USZ Universitäts Spital Zürich

Brustchirurgie

Prof. Dr. med. Nicole Lindenblatt, Stv. Klinikdirektorin

Klinik für Plastische Chirurgie und Handchirurgie, Universitätsspital Zürich



„Bare reality“ Laura Dodsworth

Brustchirurgie

- Brustvergrösserung (Mammaaugmentation)

  - Implantat

  - Eigenfett

- Bruststraffung (Mastopexie)

- Brustverkleinerung (Mammareduktion)

- Kombination (Augmentationsmastopexie)

- Brustwiederherstellung (Mammarekonstruktion)

- Brustfehlbildungen

Tages-Anzeiger

Schweiz ist Vize-Weltmeister bei Schönheits-OPs

Das Geschäft mit der käuflichen Schönheit boomt in der Schweiz. Nur in Brasilien legen sich die Menschen noch häufiger unters Messer.

Brüste vergrössern, Fett absaugen, Nase korrigieren: Immer mehr Schweizer leisten sich eine Schönheitsoperation. Bild: Gaetan Bally/Keystone

Schweiz:
59 Operationen/10.000 Einwohner

USA:
35 Operationen/10.000 Einwohner

Operationen absolut

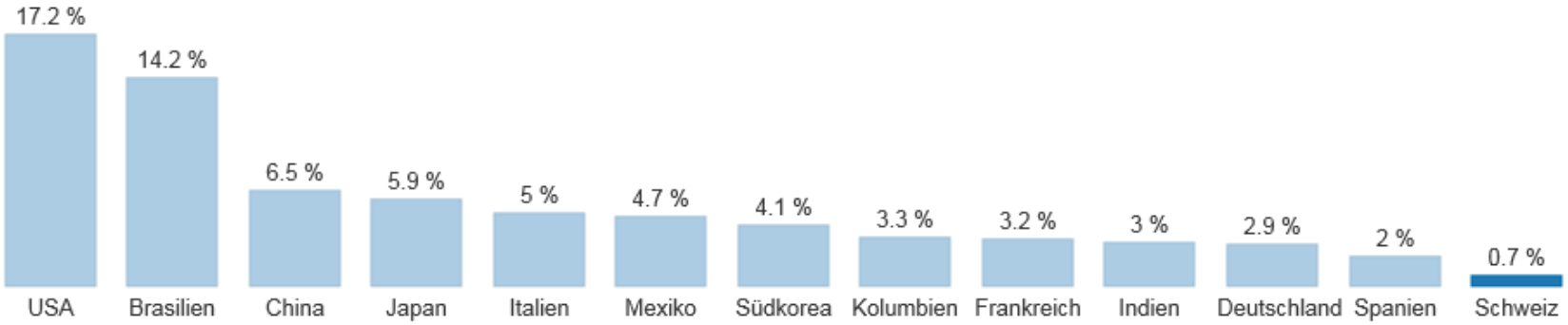

Operationen pro 10 TCH Einwohner

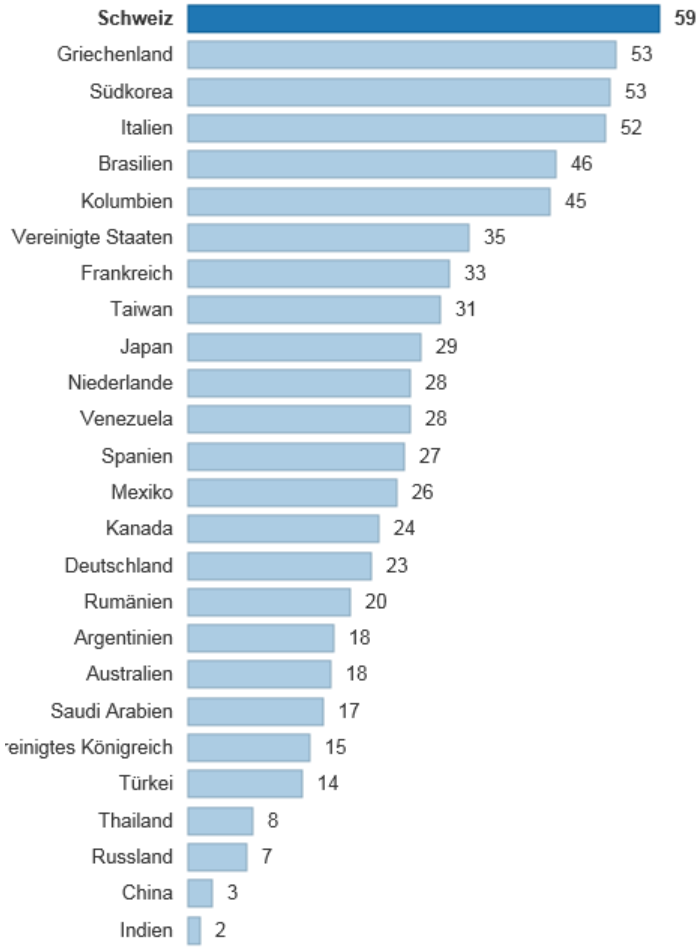

Acredis-Studie

Ästhetische Chirurgie USZ

- Kompetenz und Tradition
- Neue Techniken
- Infrastruktur für komplexe Patienten
- Service 24/7
- Behandlung vom Komplikationen

Mammaaugmentation

Brustvergrößerung

COSM
TITAN
ATEMLOSE
LUST
JOB-TEST
WELCHER
MACHT-TYP
SIND SIE?
DOLCE-VITA-MODE
GROSSES SPECIAL: WAS
MÄNNER
MACH MICH
SCHÖN, SONNE!

Präoperative Planung

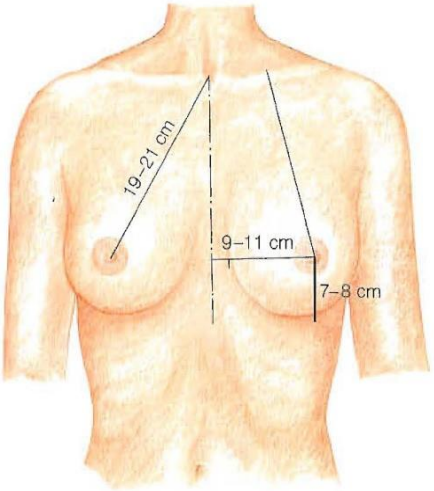

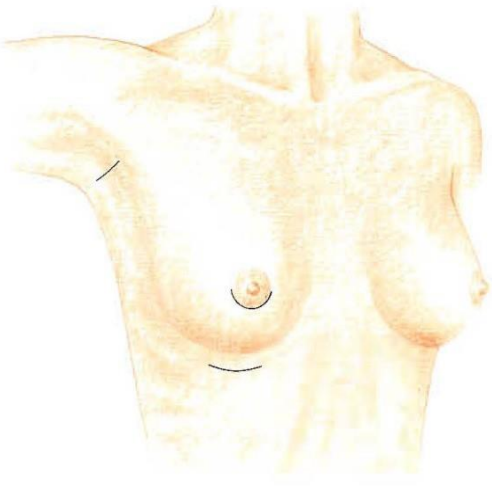

Schnittführung

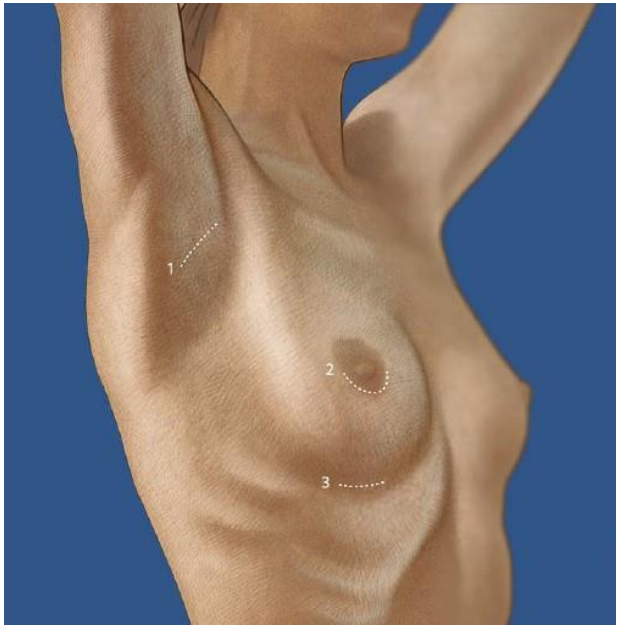

Implantatlage

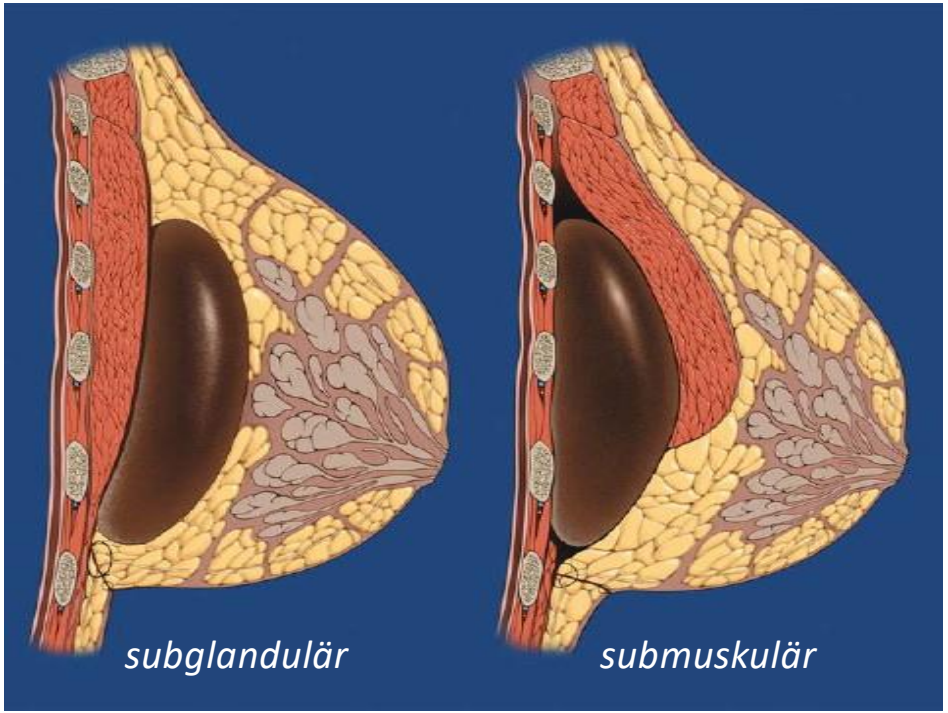

Submuskulär

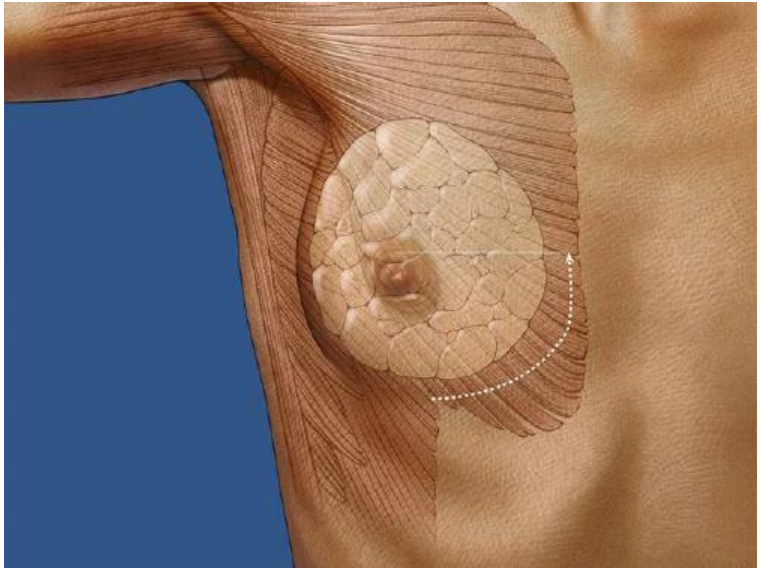

Implantat-Typ

glatt

texturiert

rund

anatomisch

Implantat-Typ



Allergan Biocell (Lost salt)
600-800 µm



Mentor Siltex (PU foam imprint)
70-150 µm



Motiva SilkSurface (Negative imprinting)
40-100 µm

Webb et al., Plast Surg. 2017
Atlan et al., J Mech Beh Bio Mat. 2018

Texturierung



USZ Universitäts Spital Zürich

Atlan et al., J Mech Beh Bio Mat. 2018

Komplikationen

- Hämatom
- Infektion
- Asymmetrie
- Narbenbidung
- Implantatruptur
- **Kapselfibrose (1.3-45%)**

  - 20-40 % Operative Revision nach Augmentation nach 10 Jahren
  - 40-70% Operative Revision nach Rekonstruktion nach 10 Jahren

- **BIA-ALCL (Breast Implant Associated Anaplastic Large Cell Lymphoma)**

  - Biofilm (Texturiert > Glatt) ?
  - Chronische Entzündung (Makrotexturierung) ?
  - Genetik ?

USZ Universitäts Spital Zürich

Mempin et al., Materials 2018

BIA-ALCL

- Seltenes T-Zell Non-Hodgkin Lymphom, CD 30+, ALK-,
- Risiko 1:3000 – 1: 30000
- > 500 Fälle weltweit, 5 Todesfälle
- Chronisches Serom oder Tumor
- In der Regel 7-10 Jahre nach Implantateinlage (0.4-20 Jahre)

- Therapie: Komplette Exzision, Chemotherapie wenn fortgeschritten

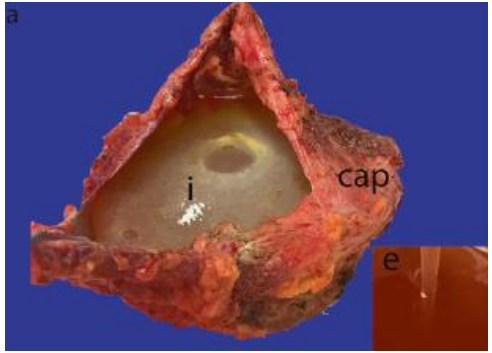

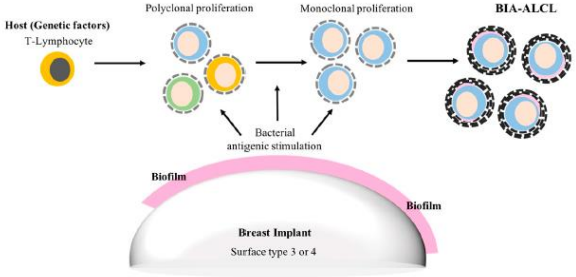

USZ Universitäts Spital Zürich

Mempin et al., Materials 2018
Quesada et al., Mod Path 2019

(Augmentations) - Mastopexie

Brustraffung mit/ohne Vergrösserung

Ptose / Pseudoptose

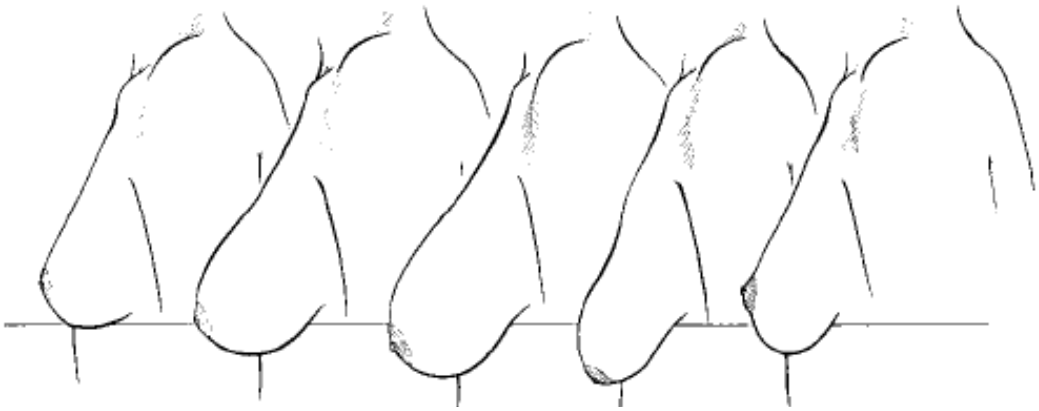

Normal Grad 1 Grad 2 Grad 2 Pseudoptose

Schnittführung

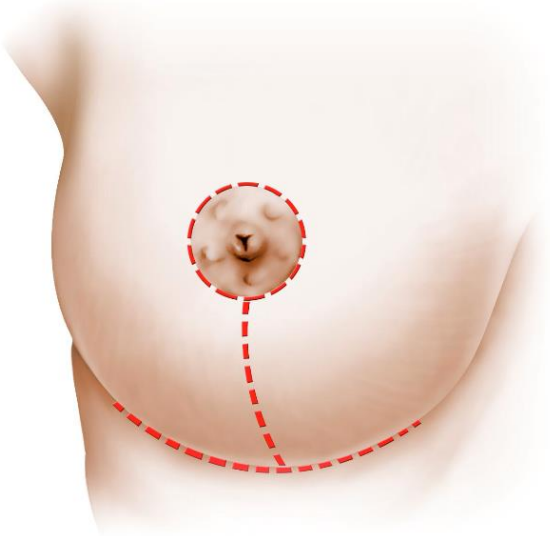

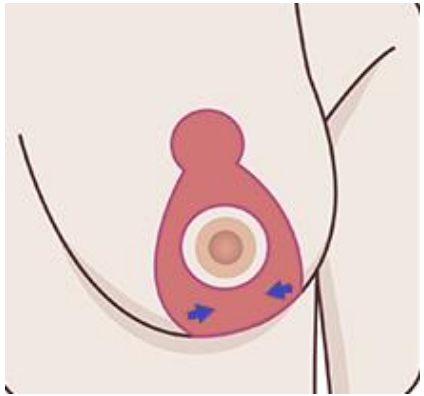

Vertikale Hautraffung

Vertikale Hautraffung

kranial *kaudal*

1 Wo

2 Mo

Mammareduktion

Brustverkleinerung

Gründe für eine Brustverkleinerung

- **Rückenbeschwerden/ Nackenbeschwerden**

  → Kopfschmerzen, Einschlafen der Arme/ Hände

- **Hautprobleme**

  Wunde Haut in Sommermonaten, Pilzinfektionen

- **Psychische Belastung**

  Blicke/ Kommentare, Meiden von Badeanstalten, Sauna, etc.

- **Ästhetik**

Leistungspflicht Krankenkasse

Kostenübernahme durch Krankenkasse

- Funktionelle Beschwerden
- BMI <25kg/m2
- Resektionsgewicht pro Seite > 500g

→ Präoperatives Kostengutsprachegesuch

- BGE 130 V 299 vom 30.04.2004

Ziele der Operation

1. Höhersetzen der Brustwarze
2. Verkleinerung des Brustwarzenhofs
3. Volumenreduktion
4. Straffung des Hautmantels

Vertikale Schnittführung

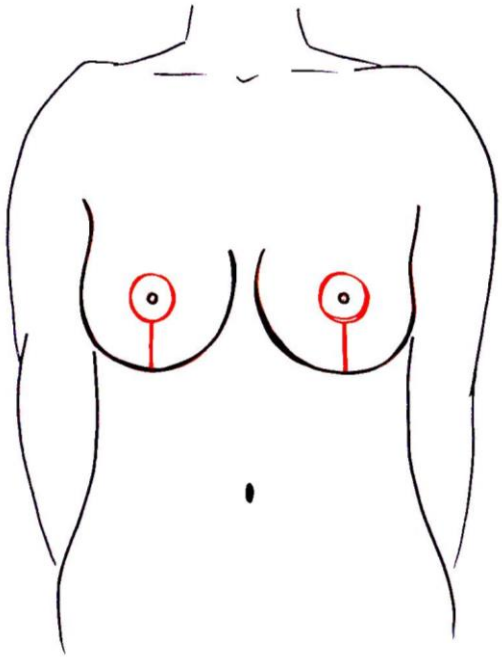

Geeignet bei

- kleineren Reduktionen
- straffem Hautmantel

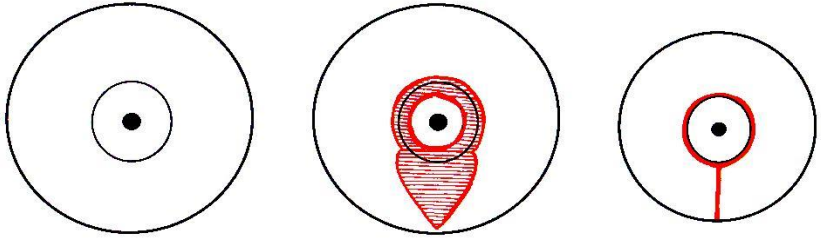

T-förmige Schnittführung

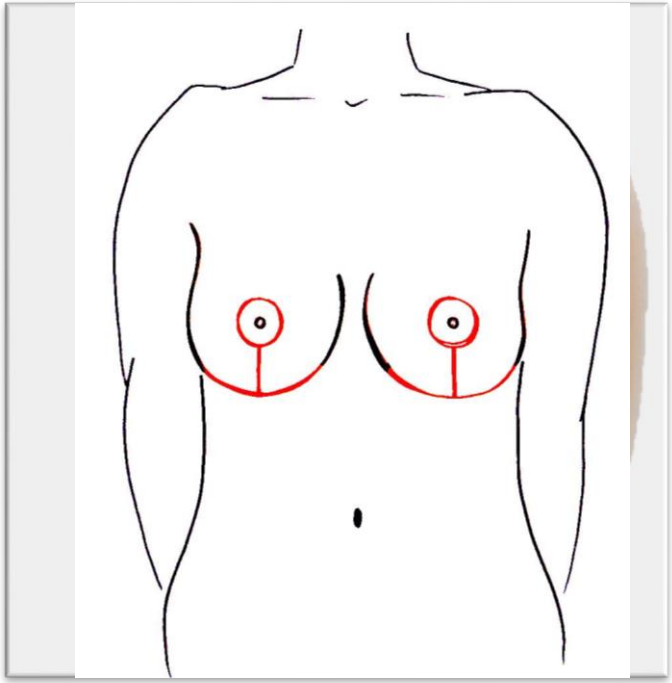

Geeignet bei

- Grossen Volumenreduktionen
- Tief stehenden Brustwarzen

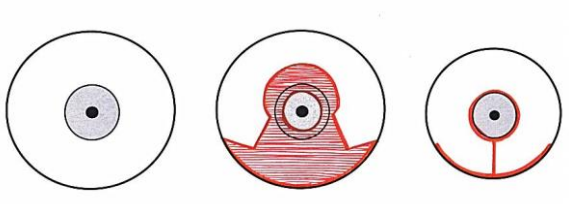

Pedikel

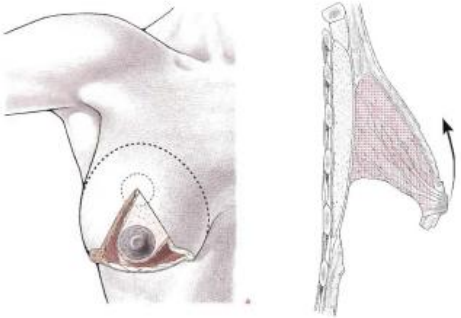

mediokranial

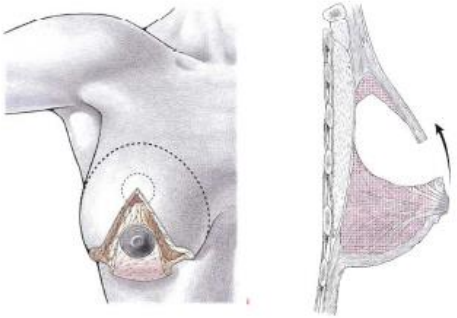

kaudal

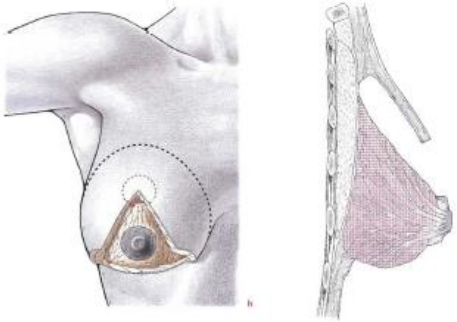

zentral

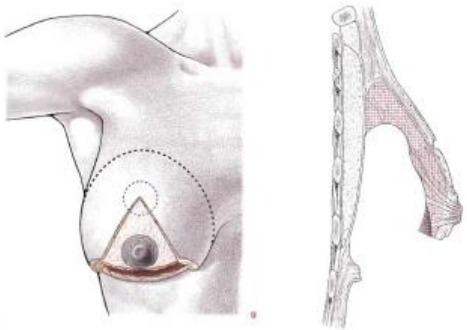

kranial

Fat grafting

Autologer Fetttransfer

Transplantation Fettgewebe

Gustav Neuber

1850-1932

Deutschland 1893 – *Fettgewebe vom Arm in die Orbita bei Osteomyelitis*

Viktor Czerny



1842-1916

Deutschland 1895 – *Transfer eines Lipoms in die Brust nach Mastektomie*

Fat grafting - Injektion

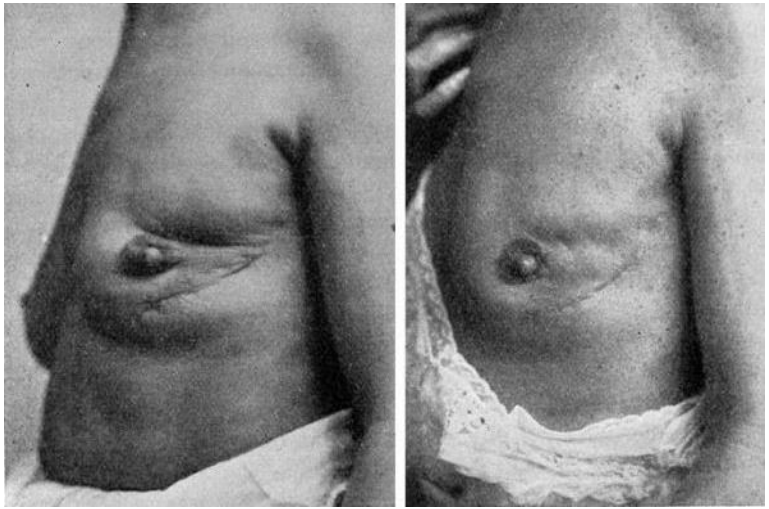

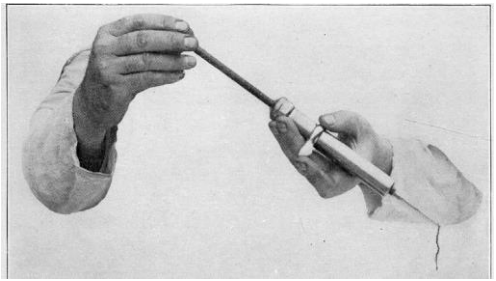

Aus: Lexer E. Die freien Transplantationen. Stuttgart, Deutschland. Enke; 1919–1924

Fat grafting - Injektion

Sydney Coleman

USA 1997 – *Lipostructure*

Gino Rigotti



Italien 2007 – *Regenerative Therapie*

Technik

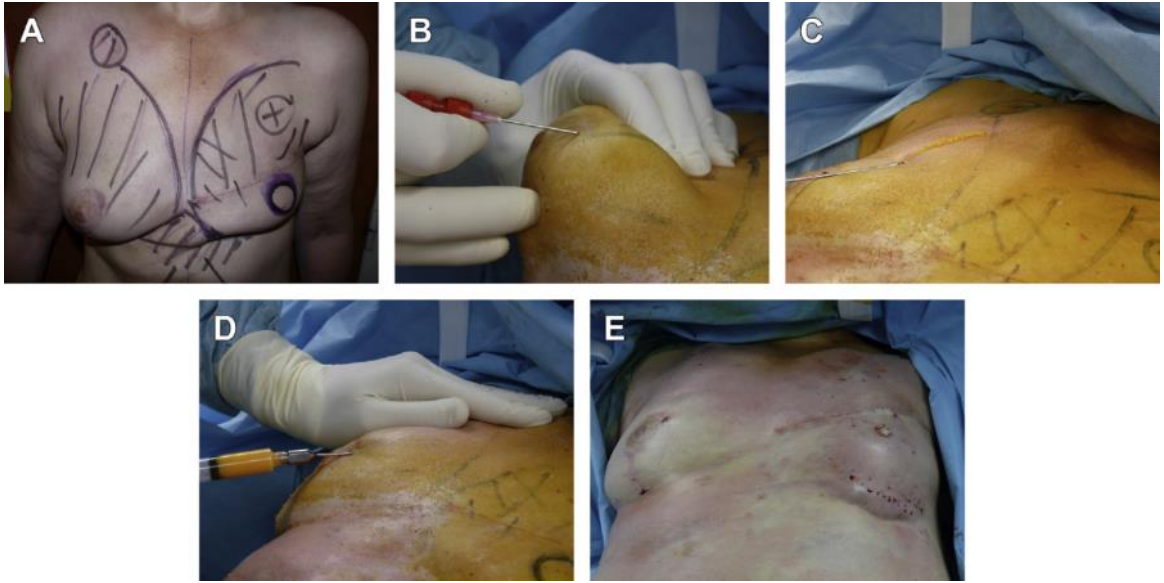

Delay et al., Cllin Plast Surg 2015

Brustrekonstruktion

Brustrekonstruktion aus der Sicht der Patientin

1. Ausmass der Chirurgie und Dauer der Erholung
2. Gutes Aussehen in Kleidung/Relation zur Krebsdiagnose
3. Vermeidung externe Prothese
4. Verwendung von eigenem Gewebe
5. Einbezug der Meinung Dritter (Partner, Arzt,..)

Wunsch nach mehr Aufklärung über Möglichkeiten und Verlauf der Rekonstruktion

Lee et al., Ann Plast Surg. 2010

Brustrekonstruktion

- Gestielte Lappenplastik
- Freie Lappenplastik
- Fat grafting
- Implantat

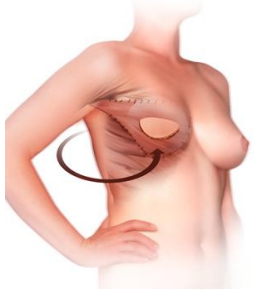

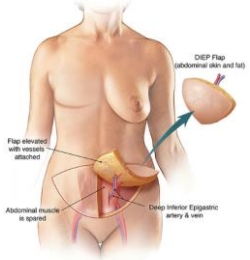

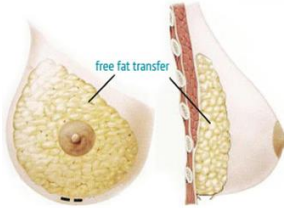

1906 M. latissimus dorsi Lappen (Tansini)



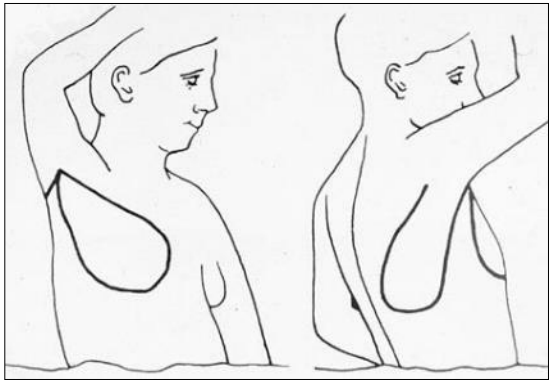

Iginio TANSINI (1855-1943)
Pavia

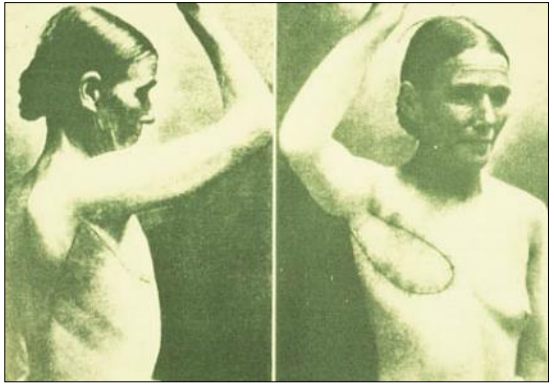

1982 gestielter TRAM (Hartrampf)

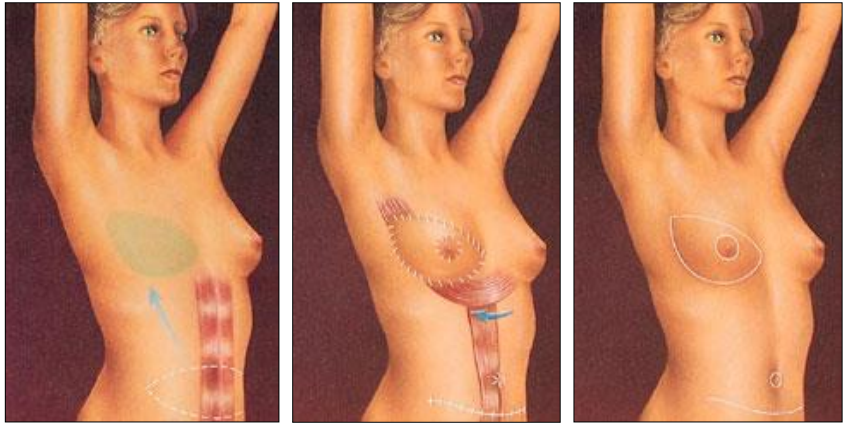

- <u>Vorteile:</u>
- direkte Blutversorgung
- grosse Lappeninsel
- Narben in der Bikinizone

- <u>Nachteile:</u>
- schädigt Bauchwand
- Evtl. Teilnekrosen

Entnahmestelle TRAM

1992 Perforatorlappenplastiken

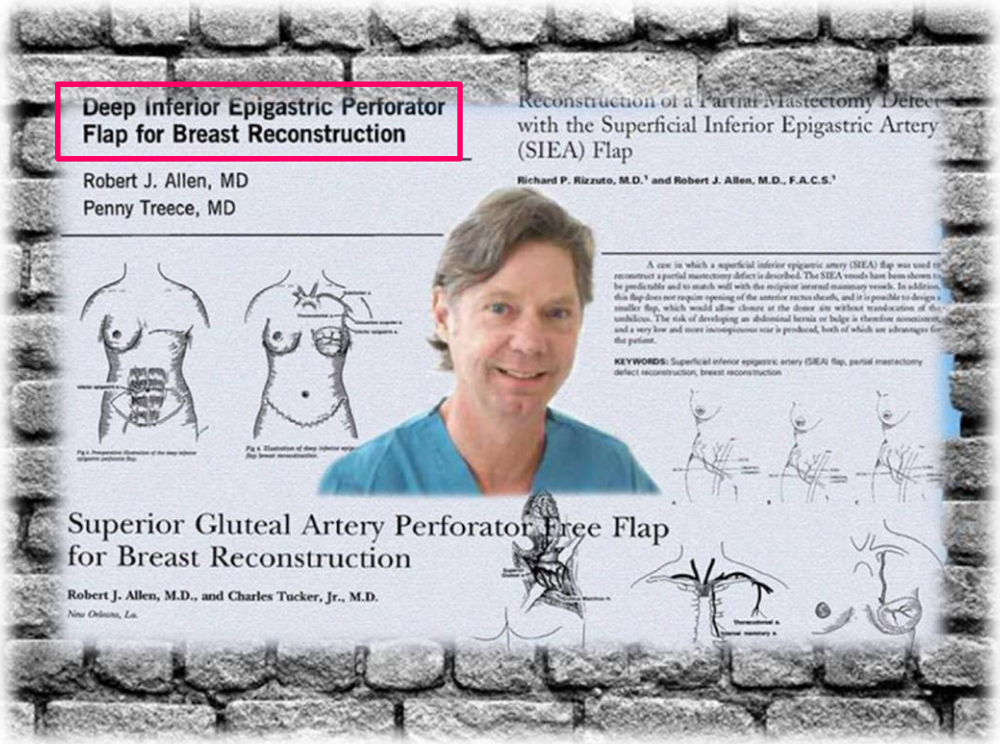

Deep Inferior Epigastric Perforator Flap (DIEP)

- Intakte Bauchwand
- Längerer Pedikel
- Freiheitsgrade Insetting
- Schnellere Mobilisation
- Kürzere Hospitalisationszeit

DIEP Lappenplastik – «Goldstandard»

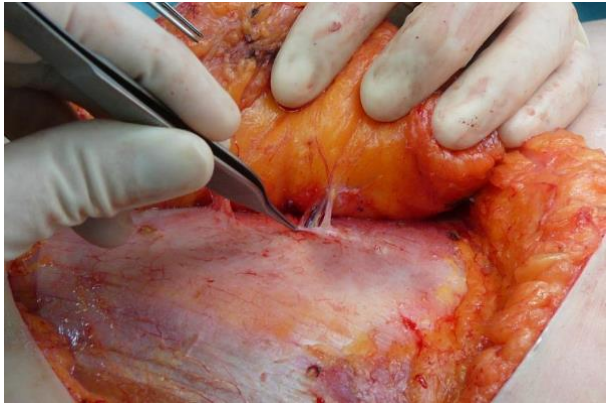

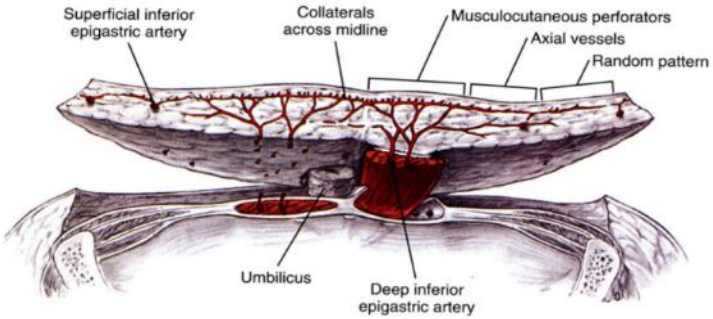

DIEP Lappenplastik

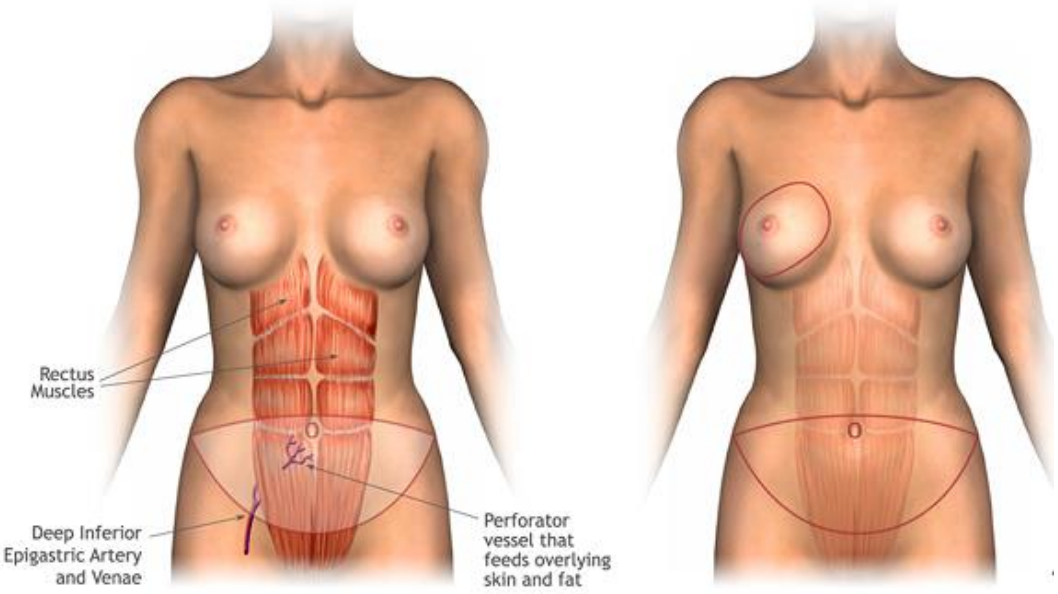

DIEP Lappenplastik

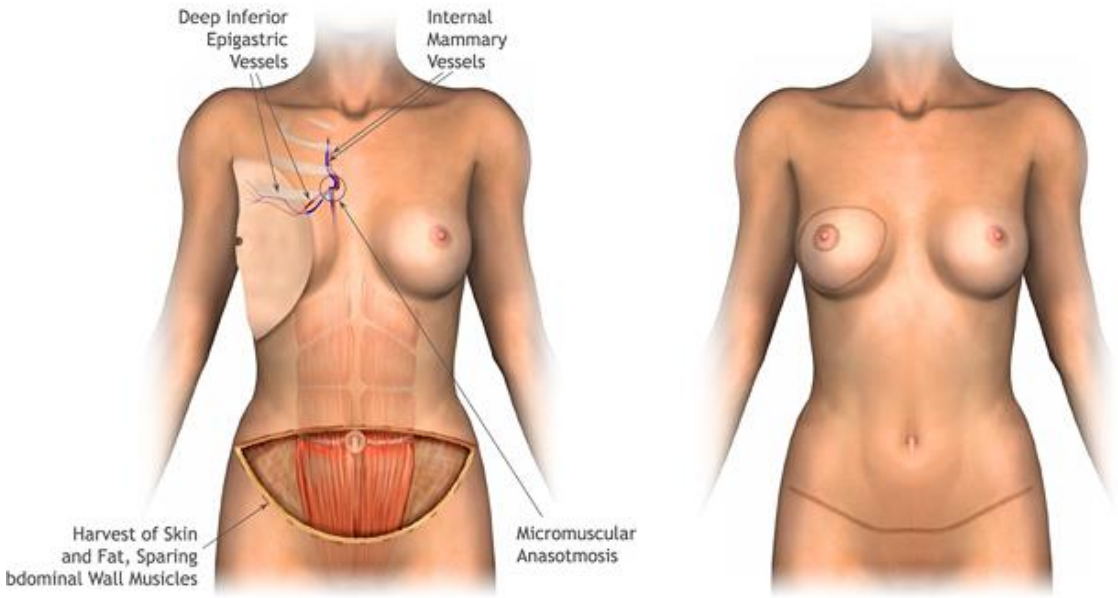

Brustrekonstruktion mit Eigengewebe

- **Entnahmestellen**
  - Bauch
  - Oberschenkel
  - Gesäss
  - Rücken

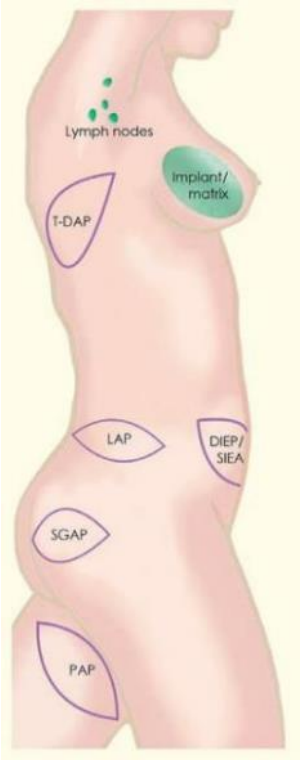

Muskellappen → Perforatorlappen

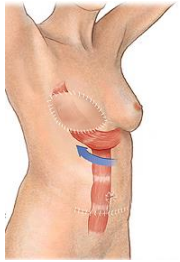

TRAM

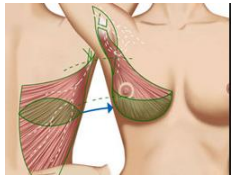

Latissimus dorsi

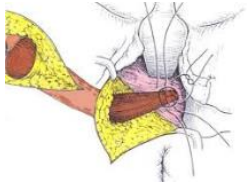

Gracilis

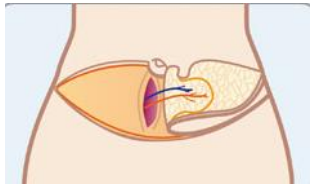

DIEP

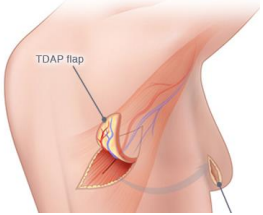

TDAP

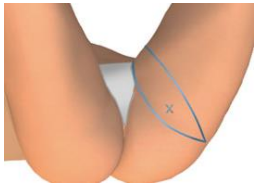

PAP

Präoperatives CT

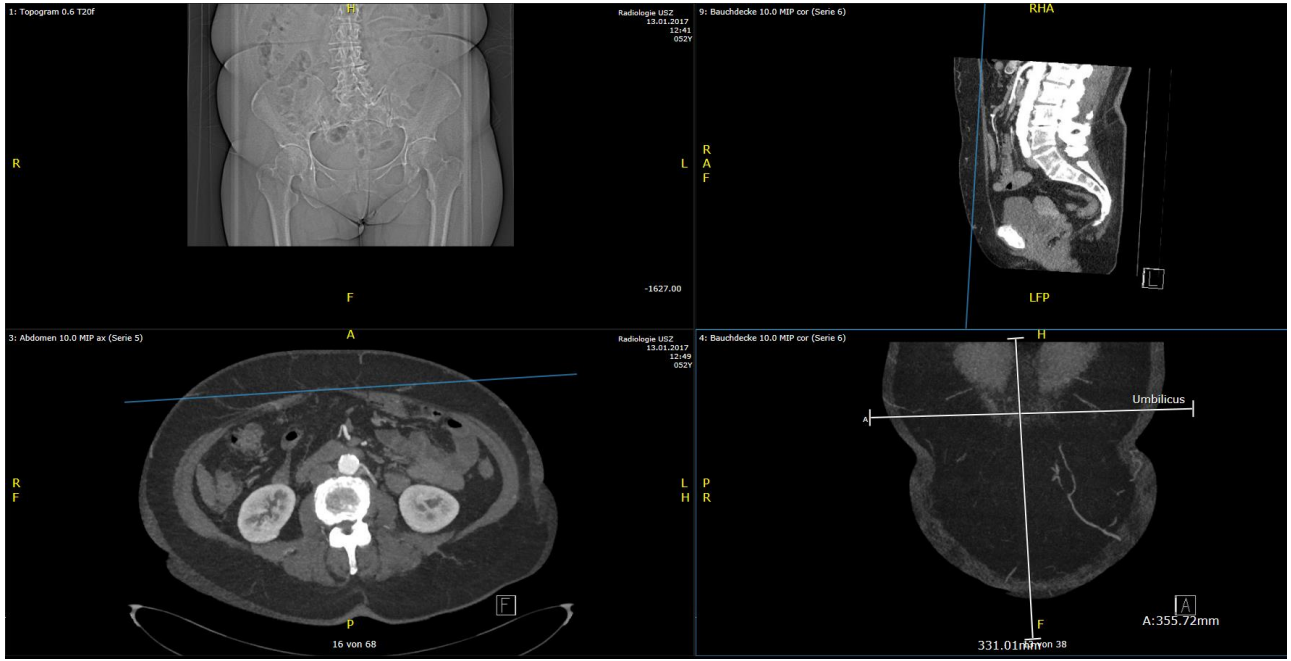

Selektion bester Perforator

DIEP und Lymphknotentransplantation

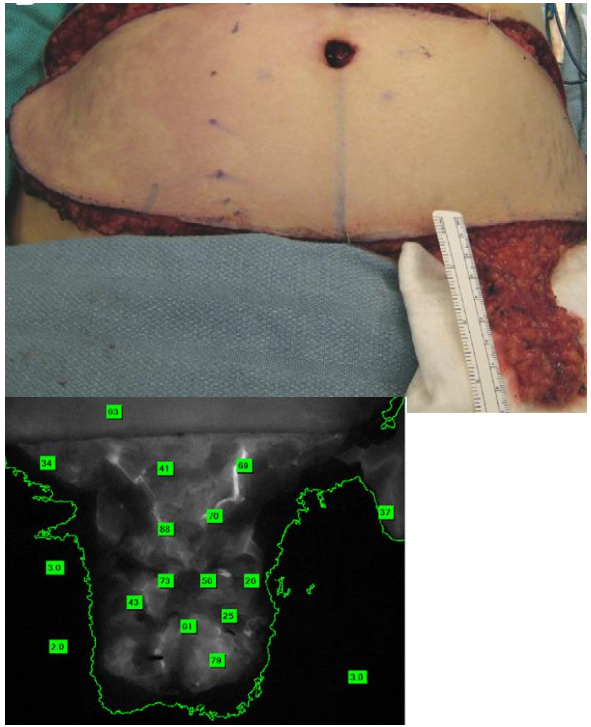

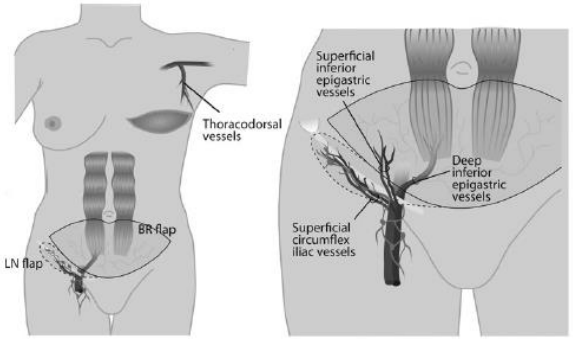

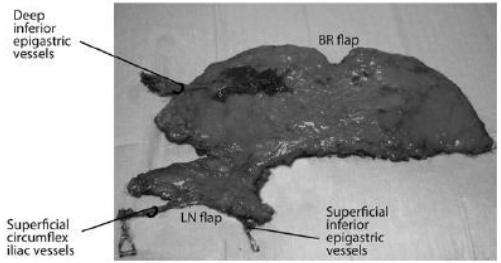

Becker et al., Clin Plast Surg 2012

Autologe Brustrekonstruction und Lymphödembehandlung

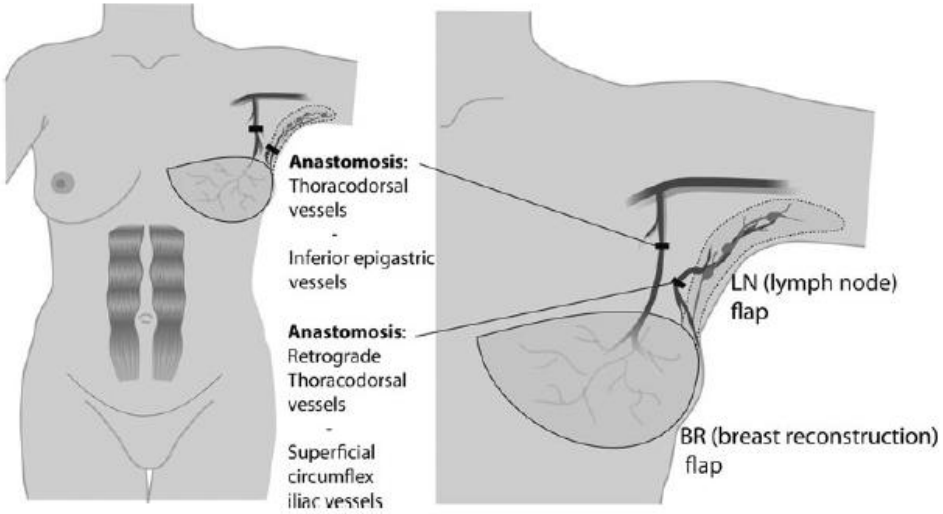

Saaristo A et al., Ann Surg. 2012

SIEA (Superficial epigastric artery) Lappenplastik

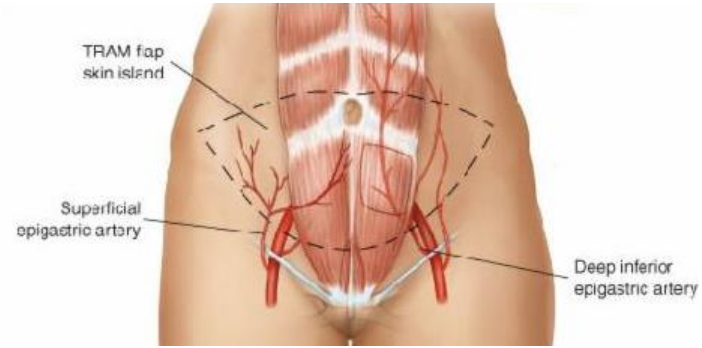

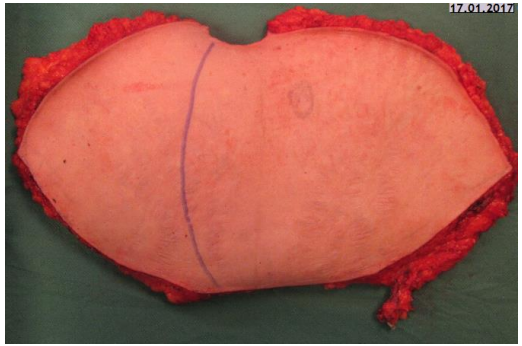

Brustrekonstruktion mit Gracilislappen/ PAP Lappen (profuda artery perforator)

Implantatrekonstruktion

glatt

texturiert

rund

anatomisch

Expander - Implantat - Gewebematrix

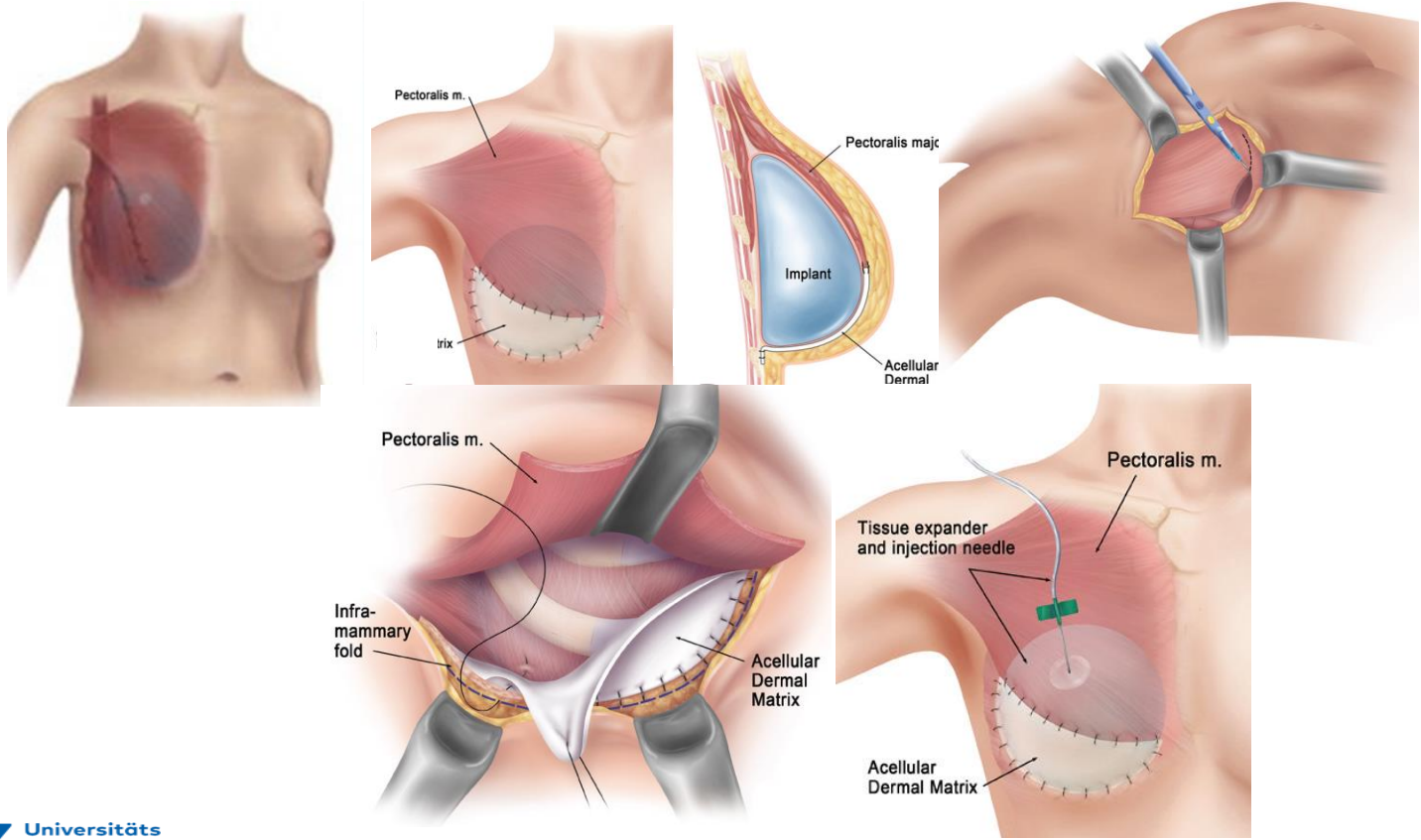

Can J Plast Surg. 2012

Gewebe- bzw. Biomatrix

- **Azelluläre Matrix (Dermis, Peritoneum)**
  - Strattice
  - Mesobiomatrix
  - Surgimend
  - Etc.
- **Synthetische Netze**

  (resorbierbar/nicht resorbierbar)
  - TIGR Matrix
  - TiLoop Bra
  - Etc.



Subpectorale Implantateinlage

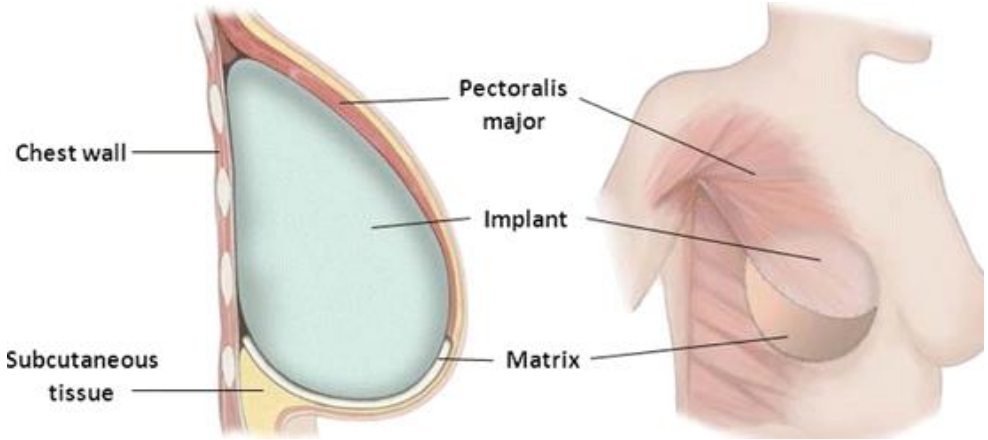

CAVE: Schmerzen, Animation M. pectoralis, Implatatdislokation, etc.

Implantatrekonstruktion und Radiotherapie

The Breast Journal

ORIGINAL ARTICLE

The Timing of Breast Irradiation in Two-Stage Expander/Implant Breast Reconstruction

Chen Yan, BA,* John P. Fischer, MD,* Gary M. Freedman, MD,† Marten N. Basta, BA,* Stephen J. Kovach, MD,* Joseph M. Serletti, MD,* Lilie Lin, MD,† and Liza C. Wu, MD*

*Division of Plastic Surgery, Perelman School of Medicine at the University of Pennsylvania, Philadelphia, Pennsylvania; †Division of Radiation Oncology, Perelman School of Medicine at the University of Pennsylvania, Philadelphia, Pennsylvania

Baker Grad III/IV Kapselfibrose

RT (Expander) vor definitivem Implantat :	**27%**
RT nach definitivem Implantat:	**36%**

Yan et al., Breast J 2016

NAC- Rekonstruktion

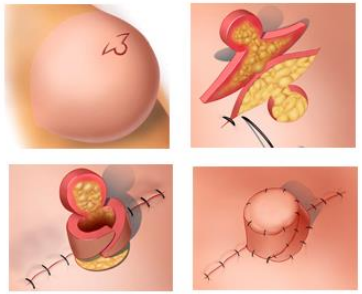

Lokale Lappenplastik , Pigmentierung und Hauttransplantat

Welche Rekonstruktion ?

USZ Universitäts Spital Zürich

Vielen Dank

http://www.plastische-chirurgie.usz.ch