6. Pflegekongress für Notfallmedizin

Kantonsspital Baden KSB

6. Pflegekongress für Notfallmedizin
Dr. Tim Bulaty / Departement interdisziplinäres Notfallzentrum 29.10.2020

EKG-Interpretation

- EKG-Interpretation im NF
- ACS
- Rhythmusstörungen
- Mentimeter-Fragen
- Take-Home
- Fragen

Kantonsspital Baden KSB

2 6. Pflegekongress für Notfallmedizin

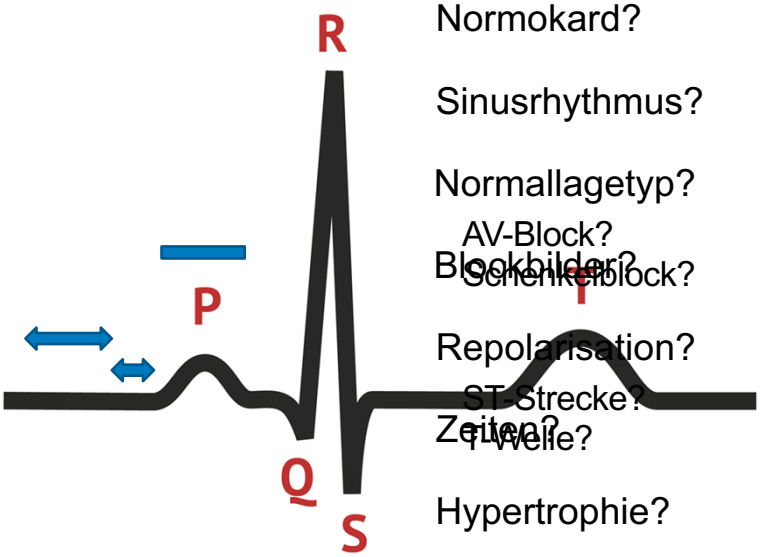

Normokard?

Sinusrhythmus?

Normallagetyp?

Blockbilder? AV-Block? Schenkelblock?

Repolarisation? ST-Strecke? T-Welle?

Zeiten?

Hypertrophie?

Kantonsspital Baden KSB

3 6. Pflegekongress für Notfallmedizin

Mann, 55j, Hypertonie, pos. FA
- Thoraxschmerzen und linker Arm seit 6h

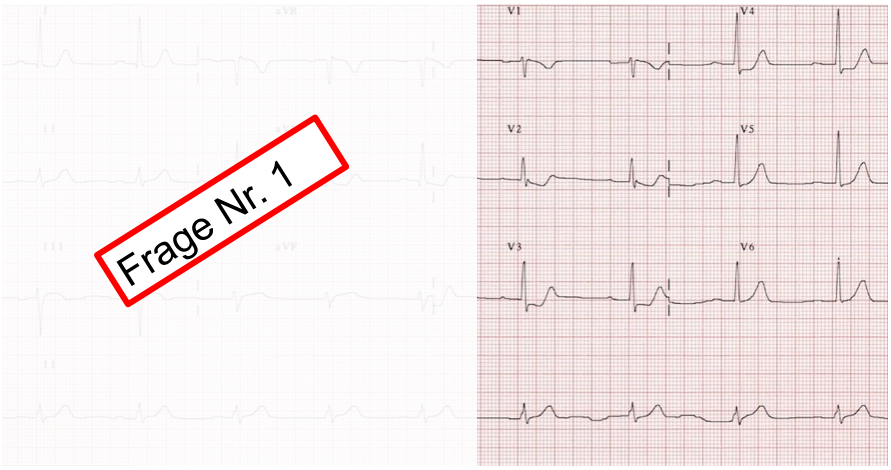

Kantonsspital Baden KSB

4 6. Pflegekongress für Notfallmedizin

Mann, 55j, Hypertonie, pos. FA
- Thoraxschmerzen und linker Arm seit 6h

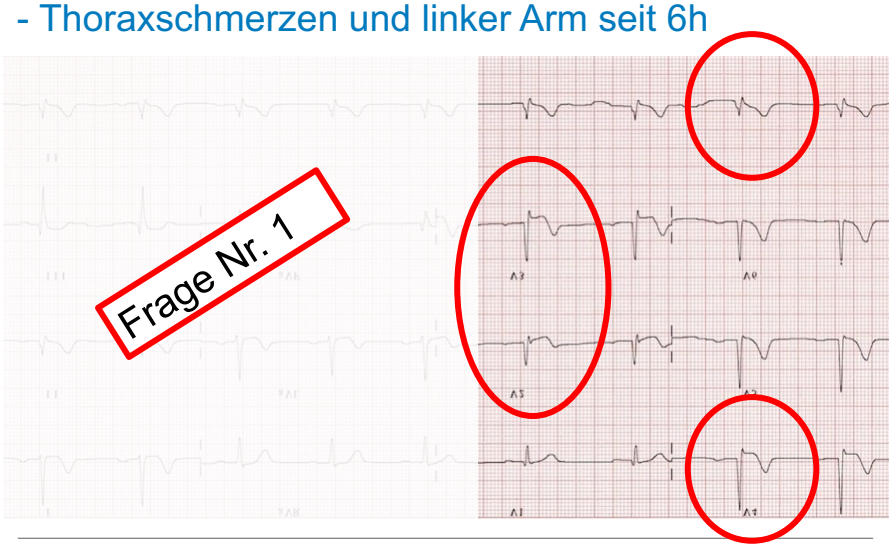

Posteriore Ableitungen

Indikation:

- ST-Senkungen V1-3/4

Interpretation V7-9:

- ST-Hebung ≥ 0.5mm
  = STEMI

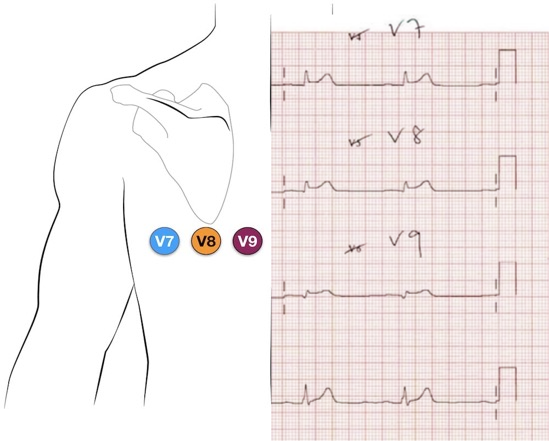

STEMI: rasch erkennen, warum eigentlich?

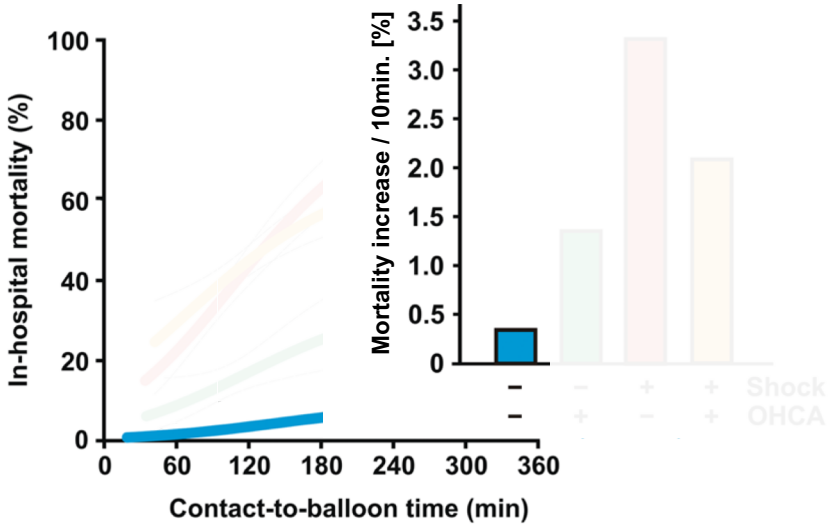

Kantonsspital Baden KSB

STEMI: EKG - Verlauf

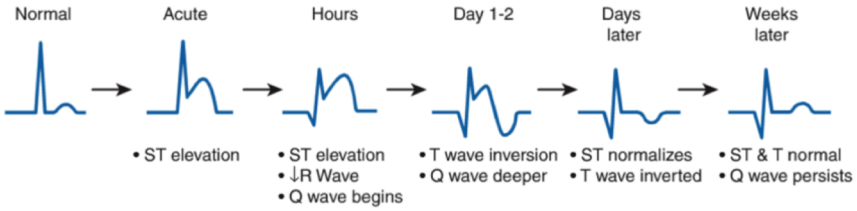

Kantonsspital Baden KSB

STEMI: Definition (ESC 2017)

Symptome vereinbar mit ACS

+

EKG-Kriterien

- ST-Hebung in ≥ 2 benachbarte
- ST-Hebung (J-Punkt) ≥ 1mm
- *Ausnahme V 2/3:* - Frauen
  - Männer
  - Männer
- *(Nicht anwendbar bei LVH ode*

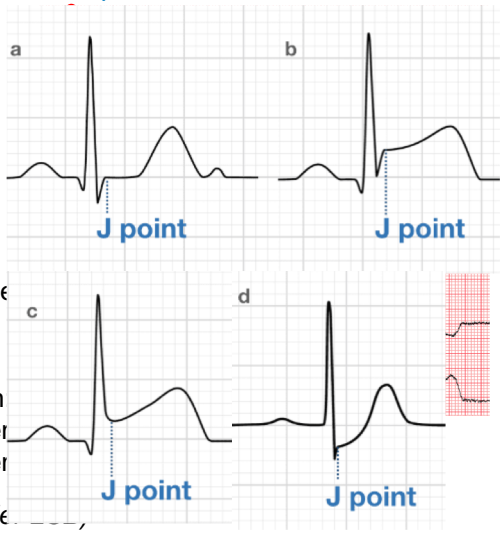

Kantonsspital Baden KSB

Frau, 48j, gesund
Synkope, epigastrische Schmerzen

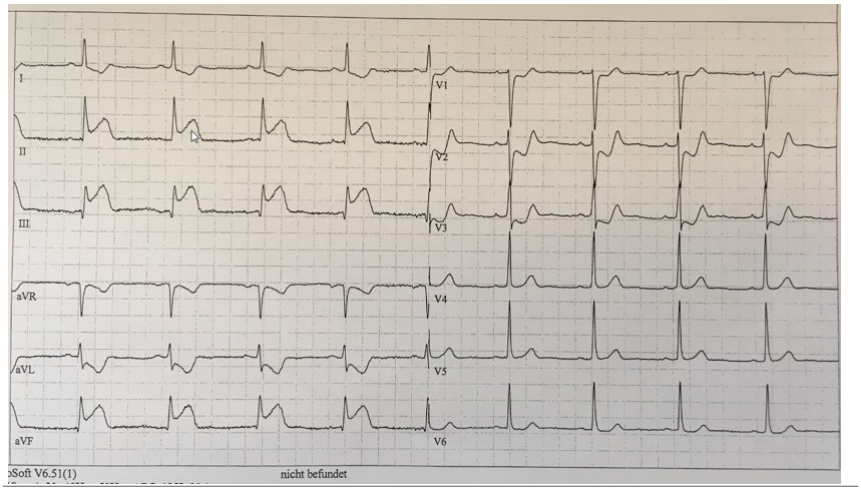

Kantonsspital Baden KSB

Rechtsherz-EKG

Indikation:

- Inferiorer STEMI
- ST-Hebung aVR / V1

Interpretation V4R:

- ST-Hebung ≥ 0.5mm = STEMI

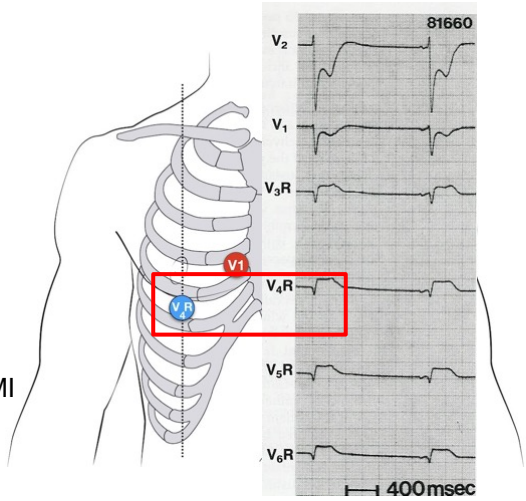

Kantonsspital Baden KSB

Rechtsherzbeteiligung bei inferiorem STEMI

Prognostisch:

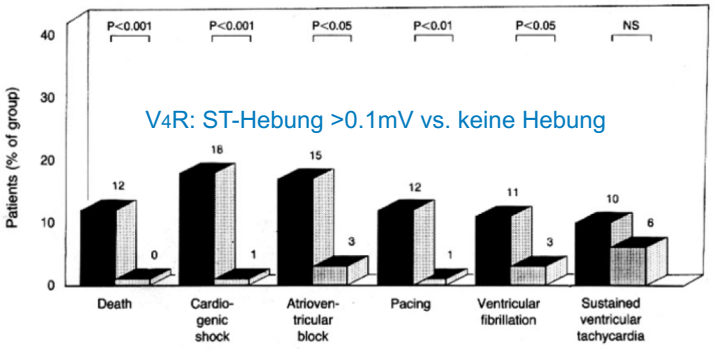

Therapeutisch:

- Volumen bei Hypotonie!
- Cave: Nitrate, Diuretika

Kantonsspital Baden KSB

Ufe luege

Abe luege

Rechts luege

Links luege

Frau, 45j, Vd.a. ACS, am EKG-Monitor

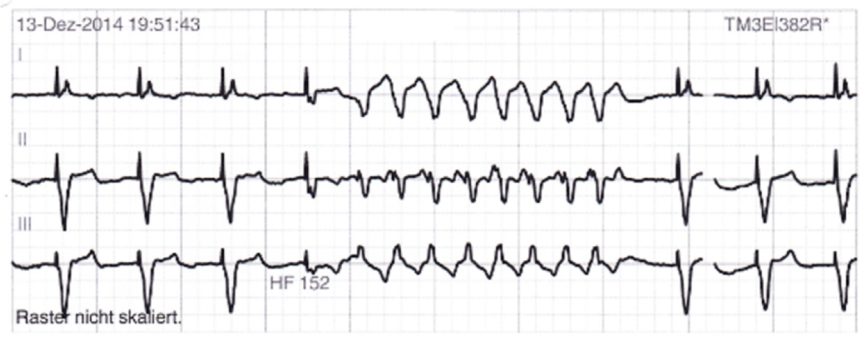

Kantonsspital Baden KSB

Mann, 41j, Schwindel und Präsynkope

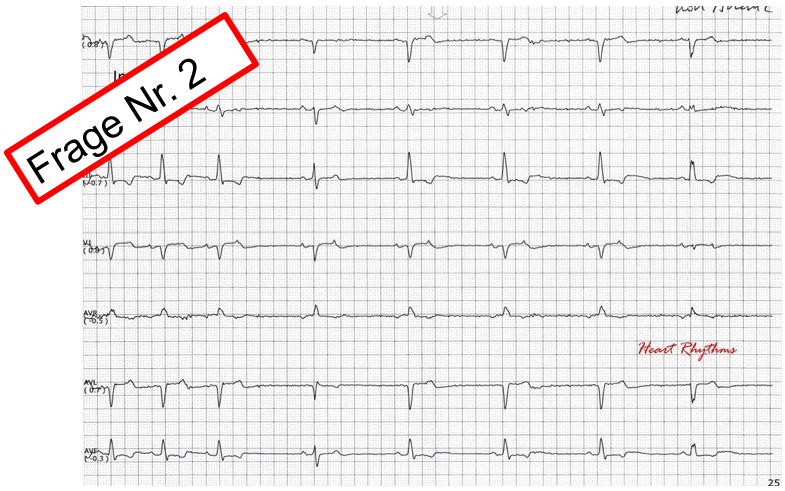

Kantonsspital Baden KSB

Mann, 41j, Schwindel und Präsynkope

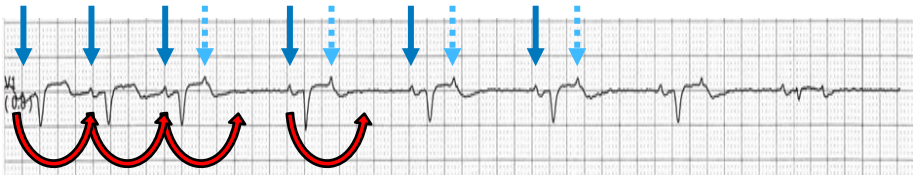

Blockierte (nicht übergeleitete) SVES

Kantonsspital Baden KSB

AV-Block II°, Typ 1 (Wenckebach)

AV-Block II°, Typ 2 (Mobitz)

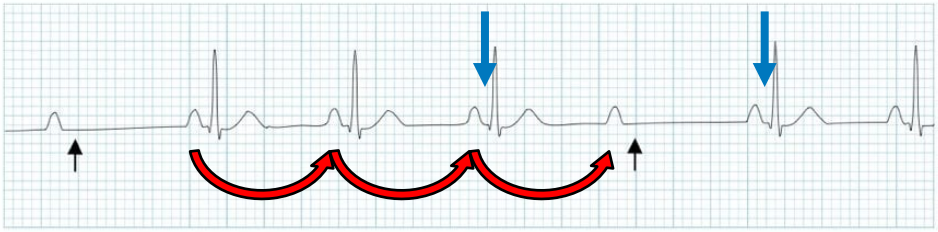

Mann, 61j, st.n. Synkope

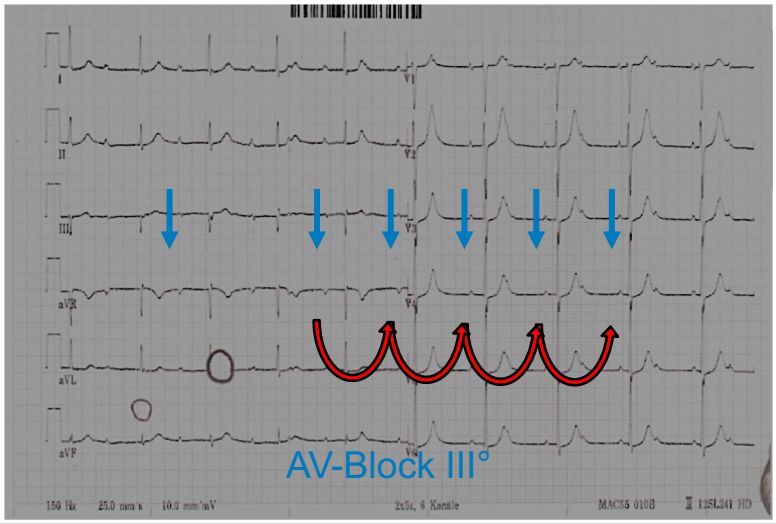

Kantonsspital Baden KSB

TAKE-HOME

- ST-Senkungen V1-3 ⇨ Posteriores EKG (V7-9)
- Inferiorer STEMI ⇨ Rechtsherz-EKG (V4R)
- AV-Block: P-Wellen, PQ-Zeiten
- Zeit nehmen für EKG-Interpretation
- Bei Vd.a. ACS: ggf. EKG wiederholen

Kantonsspital Baden KSB

Quellen:

ESC Guidelines 2017: Myocardial Infarction in Patients Presenting with ST-Segment Elevation

Scholz et al. Eur Heart J 2018: Impact of treatment delay on mortality in STEMI patients with and without haemodynamic instability: results from the German prospective, multicentre FITT-STEMI trial (20'000 pat.)

Zehender et al. NEJM 1993: Right ventricular infarction as an independent predictor of prognosis after acute inferior myocardial infarction

Einige EKG's aus Sammlung PD Dr. C. Wyss

Life in the Fast Lane (www.litfl.com)

Kantonsspital Baden KSB

Danke

tim.bulaty@ksb.ch

Kantonsspital Baden KSB