luzerner kantonsspital
KLINIK FÜR UROLOGIE LUZERN

PSMA-PET for primary staging of prostate cancer

Christoph Würnschimmel, Klinik für Urologie, Luzerner Kantonsspital

ProPSMA diagnostic phase 3 randomised study

Prostate Specific Membrane Antigen (PSMA) PET/CT

for imaging men with newly diagnosed prostate cancer

302 patients randomised with untreated prostate cancer

10 sites across Australia

50% current method: **CT + Bone scan**

50% studied method: **PSMA PET/CT**

The data supports PSMA PET/CT imaging as a replacement to current standard-of-care CT and bone scan.

1. A small radioactive molecule is injected into a vein. It finds its way to cancer cells and binds with them.

^{68}Ga-PSMA-11

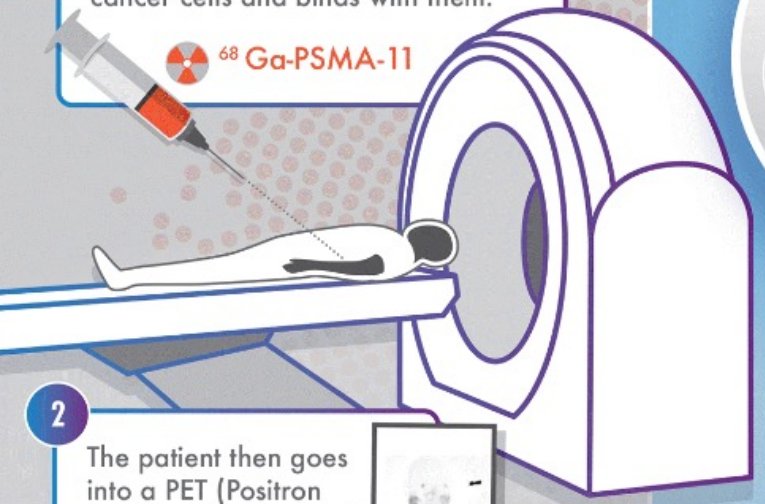

2. The patient then goes into a PET (Positron Emission Tomography) scanner that images the whole body and shows cancerous cells.

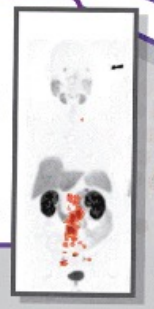

3. Patients were then followed for 6 months to determine accuracy.

SUPERIOR ACCURACY

65% CT + Bone scan

92% PSMA PET/CT

GREATER TREATMENT IMPACT

15% CT + Bone scan

28% PSMA PET/CT

FEWER UNCERTAIN RESULTS

23% CT + Bone scan

7% PSMA PET/CT

OTHER FINDINGS:

- LESS EXPOSURE TO RADIATION
- HIGH REPORTER AGREEMENT
- NO ADVERSE EFFECTS SEEN

Research sponsored by: Peter Mac Peter MacCallum Cancer Centre Victoria Australia

and proudly funded by: MOVEMBER FOUNDATION, Prostate Cancer Foundation of Australia

© Copyright 2020

THE LANCET

Hofmann et al, Prostate-specific membrane antigen PET-CT in patients with high-risk prostate cancer before curative-intent surgery or radiotherapy (proPSMA): a prospective, randomised, multicentre study
Lancet 2020; 395: 1208–16

www.swissmedicinfo.ch; Locametz

Sys review and meta analysis b/w PSMA PET and conventional imaging (44 comparative studies)

Chow et al., Eur Urol 84 (2023) 36-84

Table 3 – Patient-level and lesion-level comparison of PSMA-PET/MRI versus mpMRI and CT for nodal staging

	PSMA-PET versus mpMRI		PSMA-PET versus CT	
	PSMA-PET	mpMRI	PSMA-PET	CT
Patient-level analysis				
Sensitivity, % (95%CI)	73.7 (60.6–83.7)	38.9 (26.3–53.0)	73.2 (56.4–85.2)	38.5 (31.9–45.5)
Absolute difference (95% CI)	34.8 (16.4–53.3); $p < 0.001$[a]		34.7 (21.1–48.3); $p < 0.001$	
Specificity, % (95% CI)	97.5 (95.7–98.9)	82.6 (63.8–90.3)	97.8 (96.0–98.8)	83.6 (73.3–90.4)
Absolute difference (95% CI)	15.0 (6.7–23.2); $p < 0.001$[a]		14.1 (5.4–22.8); $p < 0.001$[a]	

Technically speaking, PSMA PET CT superior for <u>N-staging</u>

(Continued) Chow et al., Eur Urol 84 (2023) 36-84

PSMA PET vs Bone Scan

(6 studies, 541 patients)

PSMA-PET

Study	TP	FP	FN	TN	Sensitivity (95% CI)	Specificity (95% CI)
Hofman 2020	22	11	2	110	0.92 [0.73, 0.99]	0.91 [0.84, 0.95]
Janssen 2018	33	0	0	21	1.00 [0.89, 1.00]	1.00 [0.84, 1.00]
Lengana 2018	25	0	1	87	0.96 [0.80, 1.00]	1.00 [0.96, 1.00]
Pyka 2016	11	3	0	23	1.00 [0.72, 1.00]	0.88 [0.70, 0.98]
Simsek 2020	17	2	0	58	1.00 [0.80, 1.00]	0.97 [0.88, 1.00]
Zacho 2020	17	4	0	84	1.00 [0.80, 1.00]	0.95 [0.89, 0.99]
					0.98 [0.88, 0.99]	**0.96 [0.91, 0.99]**

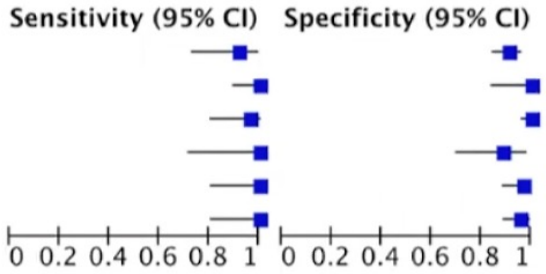

Bone Scan

Study	TP	FP	FN	TN	Sensitivity (95% CI)	Specificity (95% CI)
Hofman 2020	16	37	8	89	0.67 [0.45, 0.84]	0.71 [0.62, 0.78]
Janssen 2018	19	5	4	28	0.83 [0.61, 0.95]	0.85 [0.68, 0.95]
Lengana 2018	19	11	7	76	0.73 [0.52, 0.88]	0.87 [0.79, 0.94]
Pyka 2016	8	9	3	17	0.73 [0.39, 0.94]	0.65 [0.44, 0.83]
Simsek 2020	15	14	2	49	0.88 [0.64, 0.99]	0.78 [0.66, 0.87]
Zacho 2020	9	15	8	73	0.53 [0.28, 0.77]	0.83 [0.73, 0.90]
					0.73 [0.63, 0.81]	**0.79 [0.73, 0.84]**

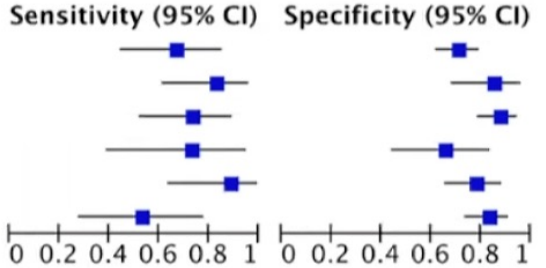

Technically speaking, PSMA PET superior for <u>bone mets</u>

(Continued) Chow et al., Eur Urol 84 (2023) 36-84

Table 2 – PSMA-PET/MRI versus MRI and PSMA-PET/CT versus MRI for detection of ECE and SVI

	PSMA-PET/MRI versus mpMRI		PSMA-PET/CT versus mpMRI	
	PSMA-PET/MRI	mpMRI	PSMA-PET/CT	mpMRI
EPE detection				
Sensitivity, % (95%CI)	78.7 (69.3–85.8)	52.9 (43.3–62.3)	51.5 (32.7–69.9)	61.0 (47.1–73.3)
Absolute difference (95% CI)	25.8 (13.2–38.5); $p < 0.001$[a]		−9.6 (−32.1 to 12.9); $p = 0.2$[a]	
Specificity, % (95% CI)	82.2 (71.3–89.5)	86.2 (76.2, 92.4)	81.1 (62.9–91.6)	85.8 (75.0–92.4)
Absolute difference (95% CI)	−4.0 (−13.7 to 5.7); $p = 0.4$[a]		−4.7 (−21.5 to 12.1); $p = 0.2$[a]	
SVI detection				
Sensitivity, % (95%CI)	66.7 (48.4–88.0)	51.0 (33.2–68.8)	44.9 (26.4–65.0)	61.8 (43.8–77.0)
Absolute difference (95% CI)	15.7 (7.6–23.8); $p = 0.02$[a]		−16.9 (−33.5 to −0.3); $p = 0.1$[a]	
Specificity, % (95% CI)	92.4 (86.8–95.7)	96.6 (92.0–98.6)	93.1 (87.4–96.3)	95.9 (92.4–97.8)
Absolute difference (95% CI)	−4.3 (−9.6 to 11.1); $p = 0.1$[a]		−2.8 (−7.8 to 2.2); $p = 0.09$[a]	

PSMA PET CT <u>local staging</u> (ECE and SVI): <u>Not superior!</u>

EAU guidelines acknowledge PSMA PET for primary staging

Summary of evidence	LE
PSMA PET/CT is more accurate for staging than CT and bone scan for high-risk disease but to date no outcome data exist to inform subsequent management.	1b

High-risk localised disease/locally-advanced disease	
Perform metastatic screening including at least cross-sectional abdominopelvic imaging and a bone-scan.	Strong
When using PSMA-PET or whole body MRI to increase sensitivity, be aware of the lack of outcome data of subsequent treatment changes.	Strong

EAU Guidelines. Edn. presented at the EAU Annual Congress Milan 2023. ISBN 978-94-92671-19-6.

Interdisciplinary EAU – EANM consensus statement on use of PSMA PET/CT in prostate cancer (21 experts)

Round 1 (original phrasing)	Round 1 (rephrased)	Round 1		Round 2	
		MS	CA	MS	CA
PSMA PET/CT should be performed in any high-risk PCa patient at staging		8	Yes		
PSMA PET/CT should be performed in some intermediate-risk PCa patients at staging	PSMA PET/CT should be considered in unfavourable intermediate-risk PCa patients at staging	7	Yes	8	Yes

Fanti et al. Eur Urol Oncol, May 2022

MS= median score,
CA = consensus achieved

1-3 Disagreement
4-6 Uncertainty
7-9 Agreement

UPDATE September 2023 (Oprea-Lager et al., Eur Urol, https://doi.org/10.1016/j.eururo.2023.09.003)

Table 2 – Delphi results after two rounds of scoring for track 1: imaging in intermediate- and high-risk PCa (histopathology proven)

	Median[a]	30th Pcentile	70th Pcentile	Consensus	Unable to score
1.9. PSMA PET-CT should replace both bone scan and abdominopelvic CT in patients with high-risk prostate cancer, undergoing initial staging.	9	9	9	Yes	1
1.15. Patients with distant metastases at diagnosis, detectable only with advanced imaging techniques (eg, PSMA PET-CT/PET-MRI or whole-body MRI), should be offered definitive local therapy along with metastasis-directed therapies, even though the impact of these techniques for prognosis and optimal patient management is unknown.	7.5	7	8	Yes	2

1-3 Disagreement
4-6 Uncertainty
7-9 Agreement

ESMO Guidelines - a very important remark!

Patients with localised disease on routine imaging should not be denied radical local treatment solely because metastatic lesions are identified on novel imaging techniques.

ESMO Clinical Practice Guideline s Prostate Cancer, https://www.esmo.org/guidelines/guidelines-by-topic/genitourinary-cancers/prostate-cancer (accessed 15 Sep 23)

The stage migration problem

1) How to interpret PSMA-PET findings? All relevant oncological outcome studies only performed conventional imaging

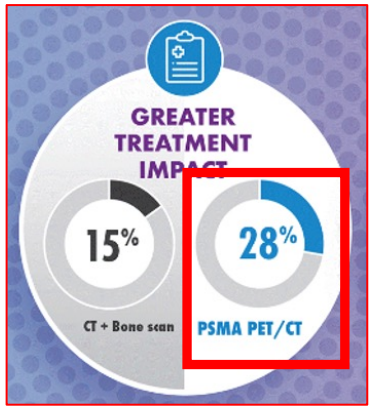

THE LANCET

Hofmann et al,
Lancet 2020; 395: 1208–16

2) Due to the accuracy of PSMA-PET, we would need novel definitions for N1 and M1 disease that distinguish those who would benefit from local Tx and those who do not

Change of treatment caused by PSMA PET…?

Join at **menti.com** use code **6759 7944**

Do Bone Scans Over Stage Disease Compared to PSMA PET at Initial Staging?

We compared interpretations of bone scans and PSMA PETs in 167 patients to determine the PPV of bone scans at various stages of disease

BS results	Initial staging	BCR	CRPC
PPV	0.43	0.77	1.00
NPV	0.94	0.74	0.56
Specificity	0.80	0.85	1.00

Of the 23 patients positive on bone scan, only 10 were positive on PSMA PET at initial staging…

Bone scans over stage patients at initial staging relative to PSMA PET

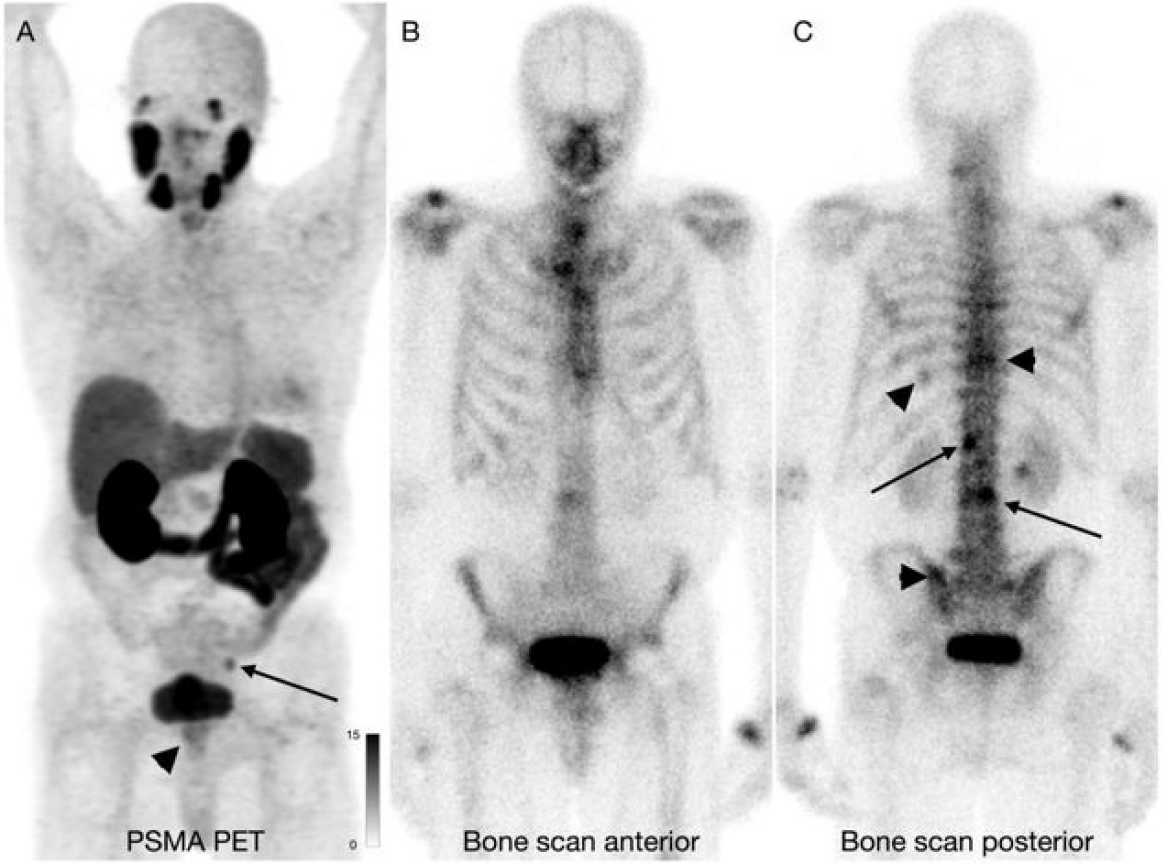

Patient with bone scan showed osseous metastases and PSMA PET was negative in the bones

Hope et al, J Nucl Med 2023

- Should
- Should
- If local
- How s s?
- At whi imens and aband

luzerner kantonsspital
KLINIK FÜR UROLOGIE LUZERN

Thank you for your attention

Dr. med. Christoph Würnschimmel

Klinik für Urologie

Luzerner Kantonsspital

christoph.wuernschimmel@luks.ch

@wuernsch

Where **may** PSMA-PET help?

Excellent marker for oncological outcomes after local treatment

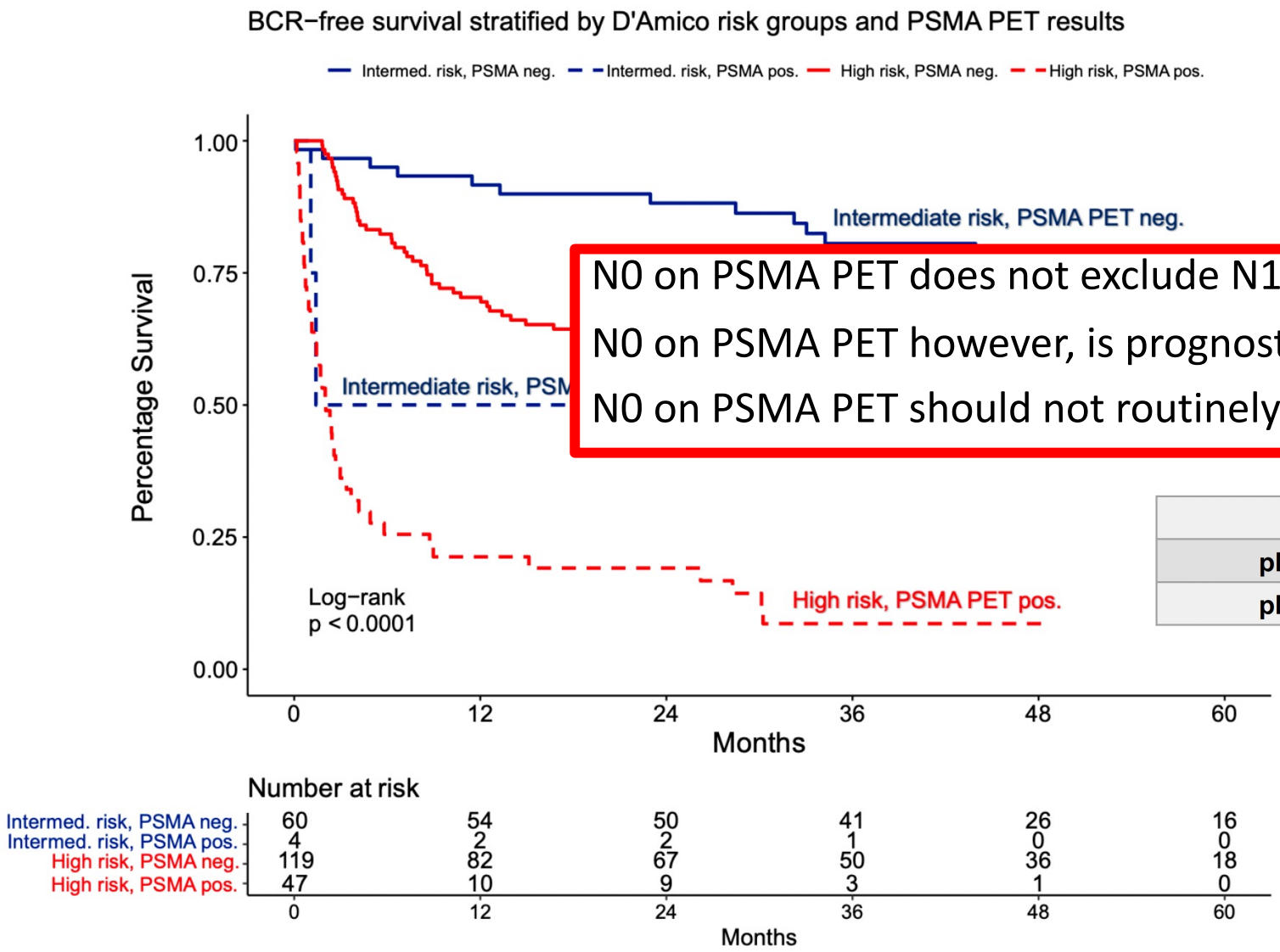

N0 on PSMA PET does not exclude N1 microscopic disease

N0 on PSMA PET however, is prognostic of better outcome

N0 on PSMA PET should not routinely be followed by omission of PLND

	miN0	miN1/N2
pN0	157	7
pN1	34	32

Chi-Square p<0.001

Amiel/Würnschimmel et al., J Urol, Jun 2021

Where **may** PSMA-PET help?

Novel risk groups incorporating PSMA PET findings

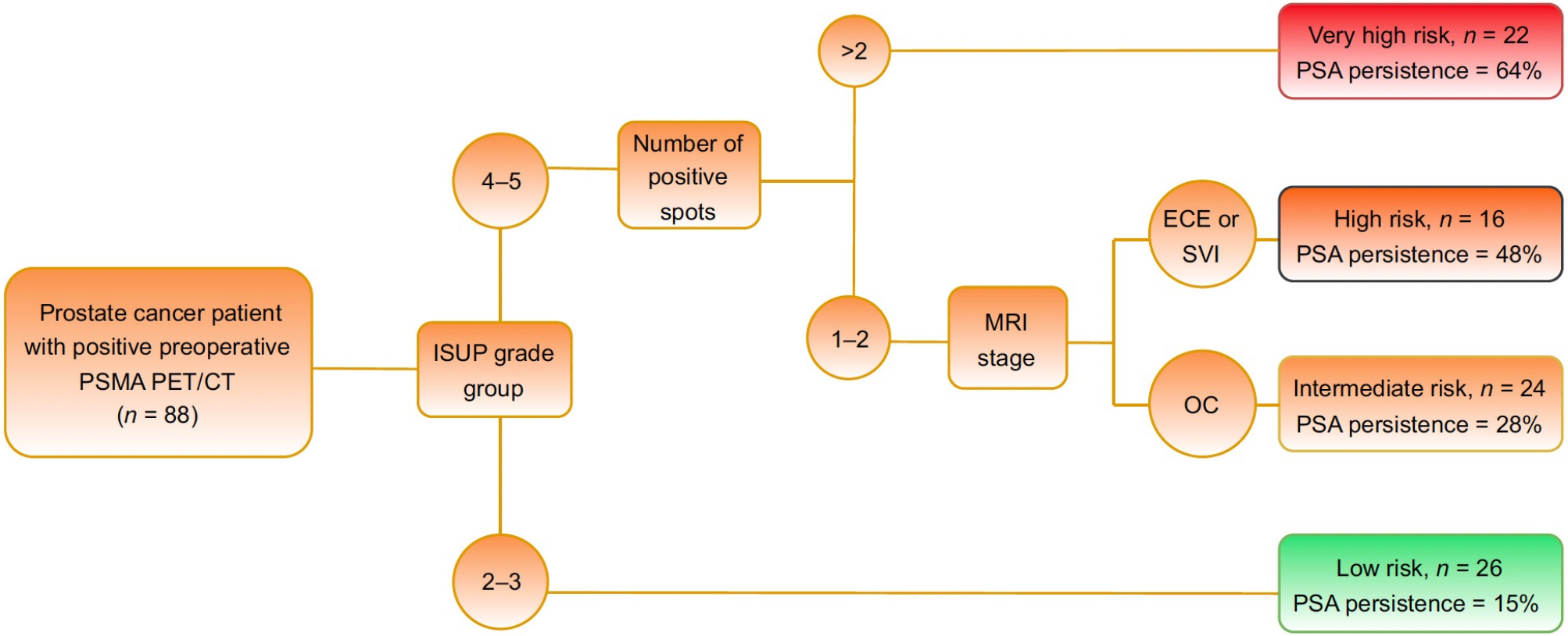

Mazzone et al., Eur Urol Oncol Aug 2023

Where **may** PSMA-PET help?

PSMA PET based nomogram helps predict oncological outcomes*

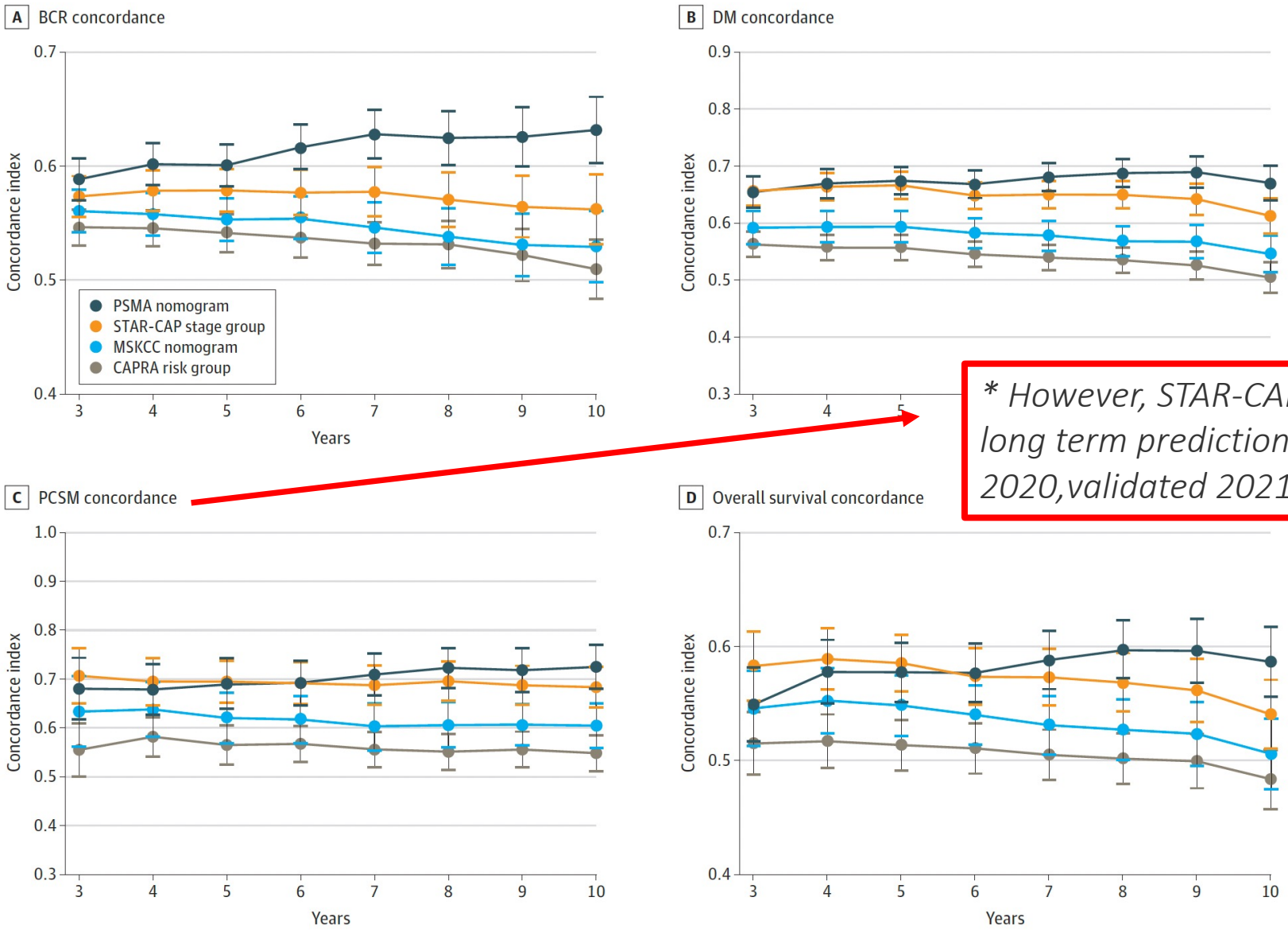

** However, STAR-CAP nomogram performs similar in the long term prediction of CSM (by Dess et al, Jama Oncology 2020,validated 2021, Würnschimmel et al, Eur Urol 2021*

Xiang et al., JAMA Netw Open. 2021

Take home

- PSMA PET, technically speaking, is the superior staging method compared to conventional imaging
- Prediction tool for oncological outcomes (patient counselling)
- No data for treatment decisions based on PSMA PET in primary staging (yet!)

Where **may** PSMA-PET help?

Prediction of nodal and metastatic upstaging after radical prostatectomy

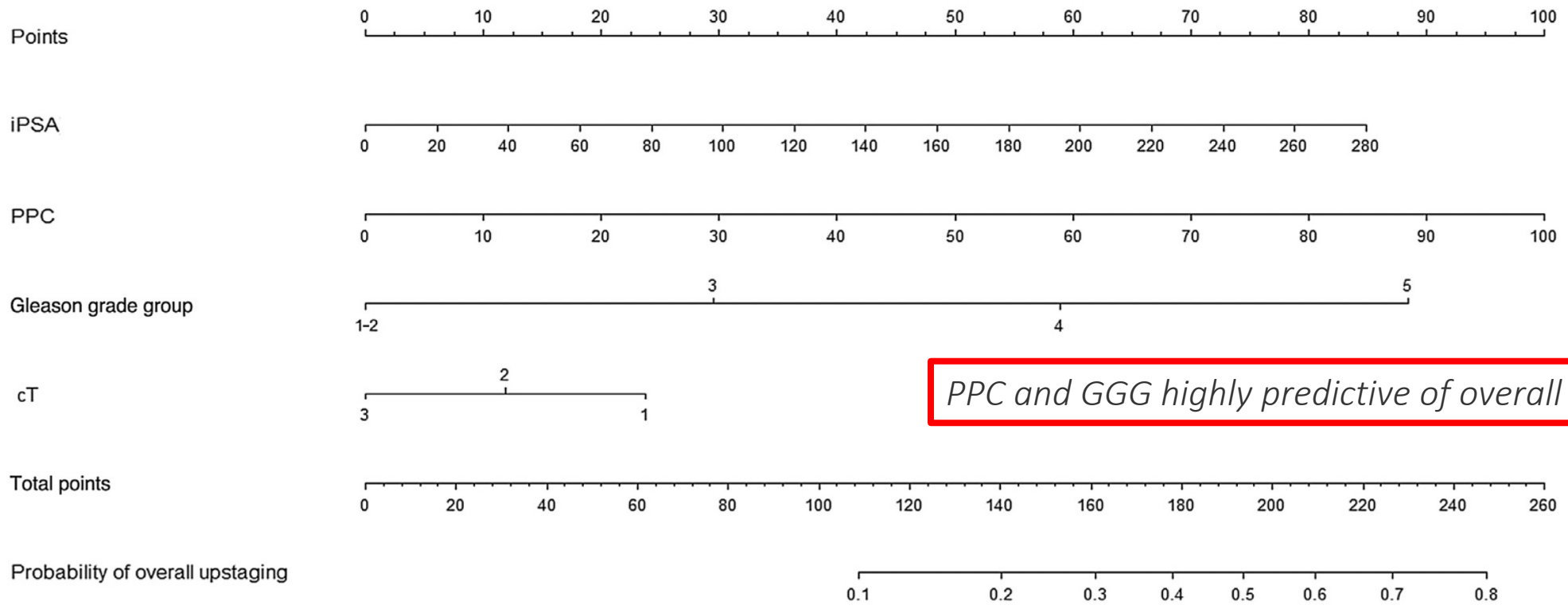

PPC and GGG highly predictive of overall upstaging

90% who had a risk <u>below the cutoff of 22%</u> could have been spared PSMA PET/CT as this model correctly predicted no upstaging.
(In other words, the predictive model missed 10% of patients who would otherwise have benefitted from PSMA PET/CT)

Nomogram based on data from two prospective PSMA PET staging + radical prostatectomy trials (all pts had negative conventional imaging!)
Hope et al, JAMA Oncol. 2021 (764 pts)
Sonni et al, J Nucl Med 2020 (197 pts)

Ma et al, Eur Urol Oncol 2022

European Association of Urology

EANM European Association of Nuclear Medicine — Biomedical Imaging and Therapy for Personalized Healthcare

SIOG International Society of Geriatric Oncology

European Society of Urogenital Radiology

ESTRO European SocieTy for Radiotherapy & Oncology

EUROPA UOMO The Voice of Men with Prostate Cancer in Europe

International Society of Urological Pathology

luzerner kantonsspital
KLINIK FÜR UROLOGIE LUZERN

EAU Guidelines: Radiotherapy for oligometastatic PCa

Offer ADT combined with non-curative prostate radiotherapy (using doses up to the equivalent of 72 Gy in 2 Gy fractions) to patients whose first presentation is M1 disease and who have low volume of disease by CHAARTED criteria/M1a disease.	Strong

	High	Low
CHAARTED (volume)	≥4 Bone metastasis including ≥1 outside vertebral column or pelvis and/or visceral metastasis	Not high

PSMA PET Costs

Costs of Imaging (± 20% for the sensitivity analysis)	PSMA PET/CT	Conventional Imaging
Belgium	719 € (575-863)	674 € (539-809)
Germany	1,102 € (882-1,322)	635 € (508-762)
Italy	1,116 € (893-1,339)	282 € (226-338)
Netherlands	2,700 € (2,160-3,240)	600 € (480-720)
USA	$ 5,438 (4,350-6,526)	$ 2,161 (1,729-2,593)

When considering favorable cost-analysis of PRO-PSMA (Australia):

- PSMA PET is <u>more expensive in Europe</u> compared to conventional imaging
- We can only assume that more precise imaging may lead to cost-savings in the long run

Holzgreve et al., Eur J Nucl Med and Mol Imaging 2023

Super-extended PLND *(Mattei/Würnschimmel et al., Eur Urol 2020)*

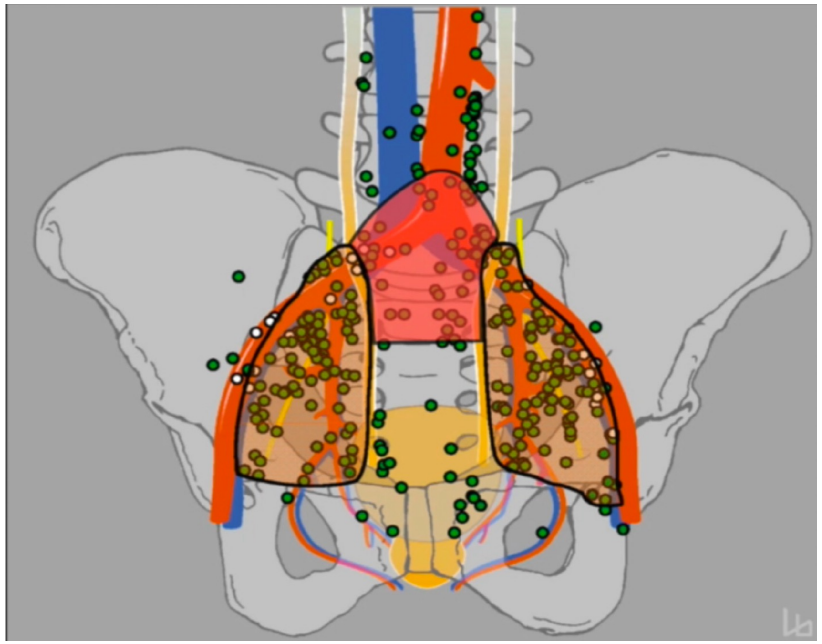

Potential evolution: PSMA-Radioguided surgery?

PSMA-RGS PROCEDURES

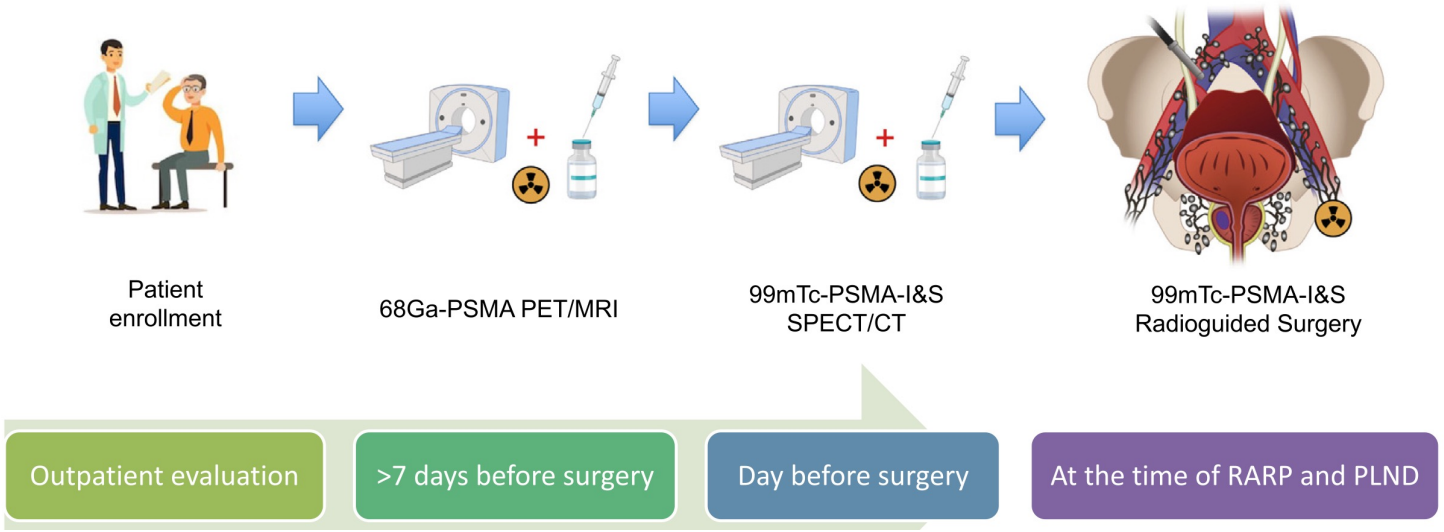

Gandaglia et al, Prostate-specific membrane antigen Radioguided Surgery to Detect Nodal Metastases in Primary Prostate Cancer Patients Undergoing Robot-assisted Radical Prostatectomy and Extended Pelvic Lymph Node Dissection: Results of a Planned Interim Analysis of a Prospective Phase 2 Study. Eur Urol Volume 82, Issue 4, October 2022, Pages 411-418

Würnschimmel et al., Quarterly J of Nucl Med and Mol Imaging 2021

www.swissmedicinfo.ch; Locametz

	Control Deaths/N	Radiotherapy Deaths/N	Interaction p value	HR (95% CI)
Metastatic burden				
Low burden	116/409	90/410	0·0098	0·68 (0·52–0·90)
High burden	252/567	257/553		1·07 (0·90–1·28)

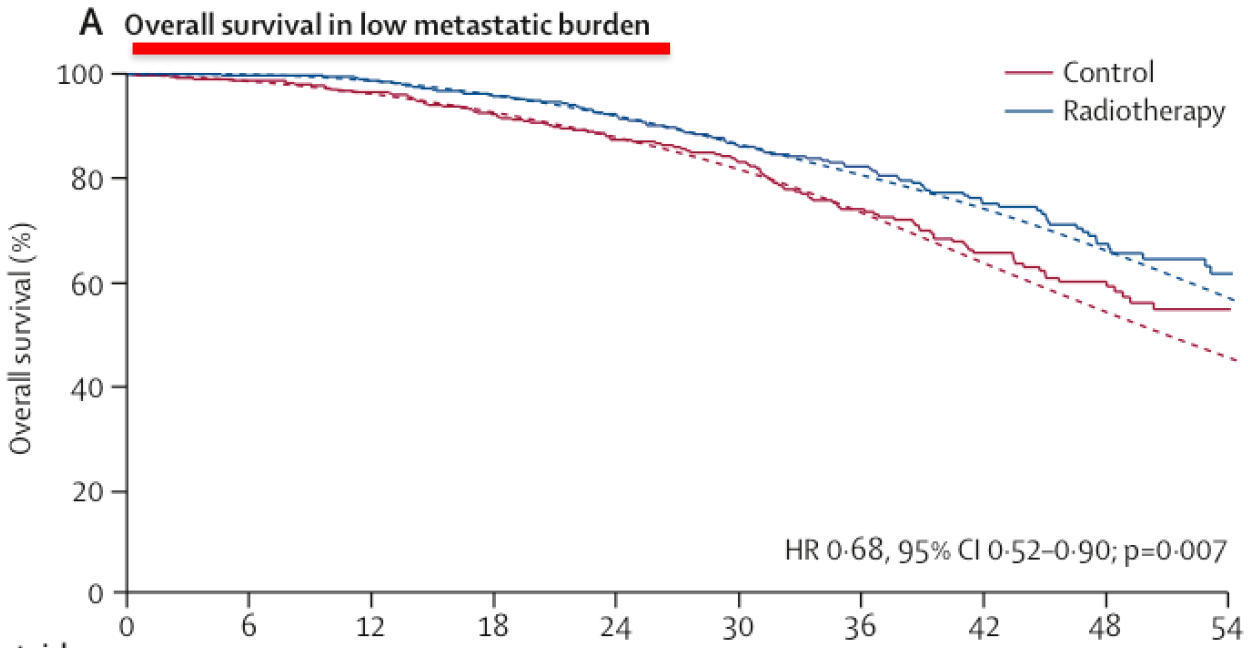

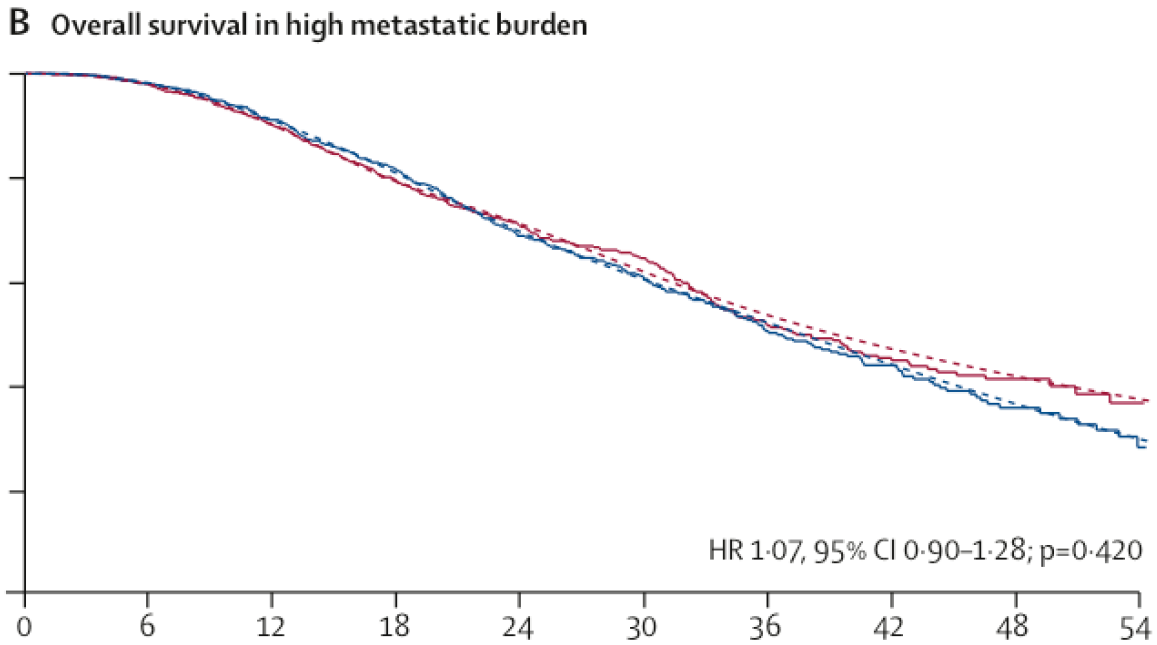

Number at risk (events)	0	6	12	18	24	30	36	42	48	54
Control	409 (5)	400 (9)	387 (17)	361 (17)	265 (12)	217 (22)	155 (16)	110 (8)	67 (5)	25
Radiotherapy	410 (1)	405 (4)	399 (12)	366 (12)	301 (19)	242 (10)	200 (15)	137 (11)	77 (5)	25

	0	6	12	18	24	30	36	42	48	54
Control	567 (11)	547 (42)	500 (58)	428 (41)	312 (27)	245 (43)	161 (20)	100 (7)	48 (3)	13
Radiotherapy	553 (10)	537 (38)	487 (48)	424 (59)	282 (30)	216 (31)	146 (19)	90 (14)	44 (5)	20

Parker et al, Lancet 2018; 392: 2353–66

Surgery for oligometastatic PCa?

- 200 randomised pts
- 100 ADT und 96 ADT + local therapy
- **85 RP** and 11 RTx
- (contamination: 17 received local therapy in ADT arm)

5. Conclusions

In conclusion, based on the evidence of this study, RP should be considered by experienced urologists as an alternative strategy to improve outcome for newly diagnosed OMPCa patients.

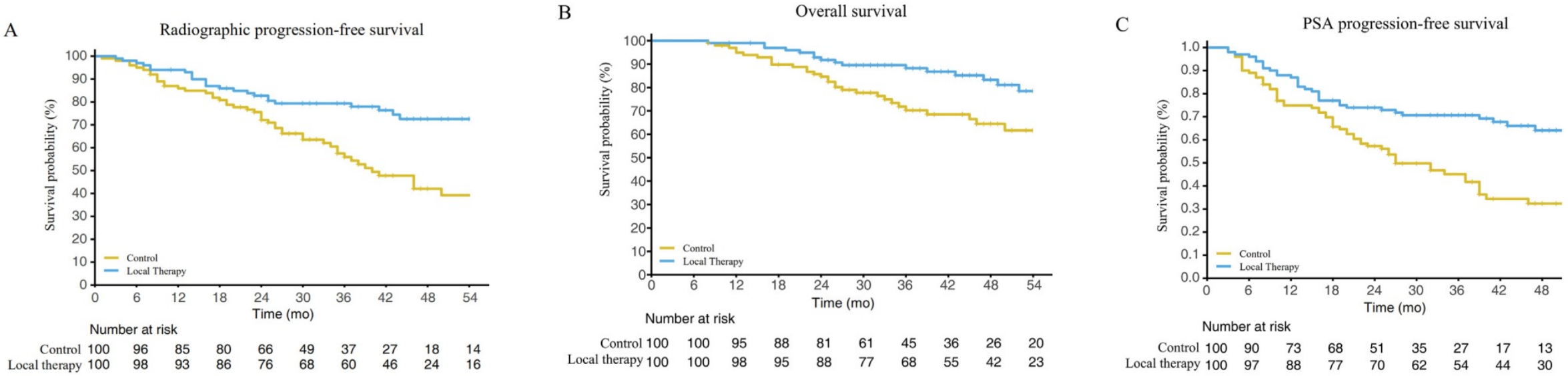

Dai et al, Eur Urol Oncol 2022

Neoadjuvant ^{177}Lu-PSMA-I&T Radionuclide Treatment in Patients with High-risk Prostate Cancer Before Radical Prostatectomy: A Single-arm Phase 1 Trial

Golan et al

EUROPEAN UROLOGY ONCOLOGY 6 (2023) 151–159

Eur Urol Focus. 2021 Mar;7(2):234-237. doi: 10.1016/j.euf.2020.09.021. Epub 2020 Nov 7.

Clinical Trial Protocol for LuTectomy: A Single-arm Study of the Dosimetry, Safety, and Potential Benefit of ^{177}Lu-PSMA-617 Prior to Prostatectomy

Nattakorn Dhiantravan [1], John Violet [2], Renu Eapen [3], Omar Alghazo [4], Mark Scalzo [5], Price Jackson [6], Simon P Keam [7], Catherine Mitchell [8], Paul J Neeson [9], Shahneen Sandhu [10], Scott G Williams [2], Daniel Moon [11], Nathan Lawrentschuk [12], Arun Azad [10], Michael S Hofman [13], Declan G Murphy [14]

SURGERY IN MOTION | VOLUME 82, ISSUE 4, P411-418, OCTOBER 2022

Download Full Issue

PDF

Prostate-specific membrane antigen Radioguided Surgery to Detect Nodal Metastases in Primary Prostate Cancer Patients Undergoing Robot-assisted Radical Prostatectomy and Extended Pelvic Lymph Node Dissection: Results of a Planned Interim Analysis of a Prospective Phase 2 Study

Giorgio Gandaglia • Elio Mazzone • Armando Stabile • ... Fijs W.B. van Leeuwen • Francesco Montorsi • Alberto Briganti • Show all authors

Open Access • Published: July 22, 2022 • DOI: https://doi.org/10.1016/j.eururo.2022.06.002 •

ORIGINAL ARTICLE | VOLUME 35, ISSUE 10, E628-E635, OCTOBER 2023

Download Full Issue

The STAMPEDE2 Trial: a Site Survey of Current Patterns of Care, Access to Imaging and Treatment of Metastatic Prostate Cancer

H. Abdel-Aty • L. O'Shea • C. Amos • L.C. Brown • E. Grist • G. Attard • N. Clarke • W. Cross • C. Parker • M. Parmar • N.vas As • N. James • Show less

Published: July 21, 2023 • DOI: https://doi.org/10.1016/j.clon.2023.07.009 • Check for updates

Lesion Dosimetry for [^{177}Lu]Lu-PSMA-617 Radiopharmaceutical Therapy Combined with Stereotactic Body Radiotherapy in Patients with Oligometastatic Castration-Sensitive Prostate Cancer

Milan Grkovski, Joseph A. O'Donoghue, Brandon S. Imber, George Andl, Cheng Tu, Daniel Lafontaine, Jazmin Schwartz, Maria Thor, Michael J. Zelefsky, John L. Humm and Lisa Bodei

Journal of Nuclear Medicine August 2023, jnumed.123.265763; DOI: https://doi.org/10.2967/jnumed.123.265763

Super-extended PLND *(Mattei/Würnschimmel et al., Eur Urol 2020)*

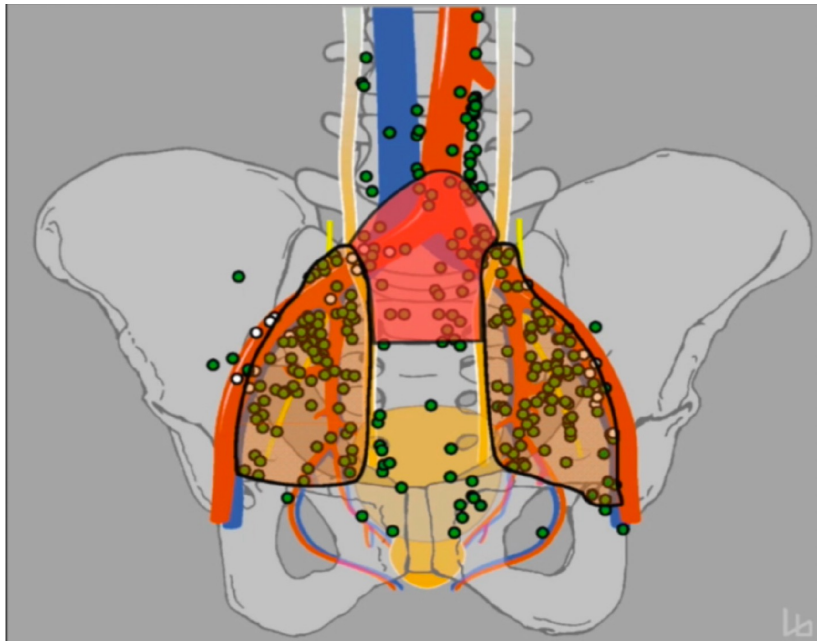

Potential evolution: PSMA-Radioguided surgery?

PSMA-RGS PROCEDURES

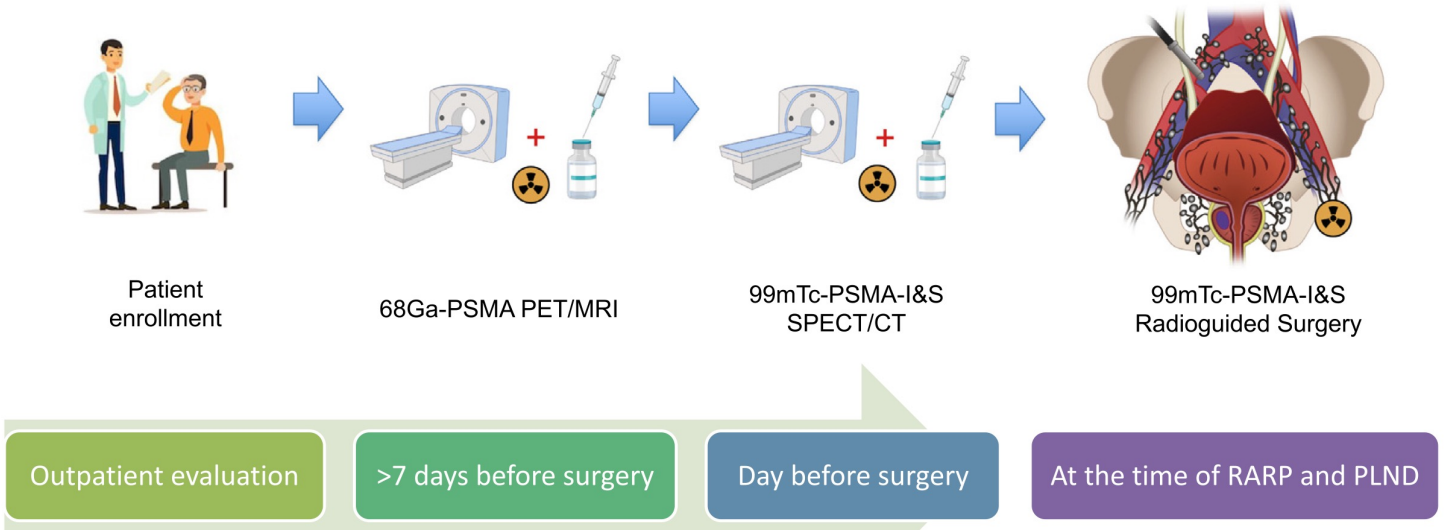

Gandaglia et al, Prostate-specific membrane antigen Radioguided Surgery to Detect Nodal Metastases in Primary Prostate Cancer Patients Undergoing Robot-assisted Radical Prostatectomy and Extended Pelvic Lymph Node Dissection: Results of a Planned Interim Analysis of a Prospective Phase 2 Study. Eur Urol Volume 82, Issue 4, October 2022, Pages 411-418

Würnschimmel et al., Quarterly J of Nucl Med and Mol Imaging 2021

www.swissmedicinfo.ch; Locametz

NCCN guidelines endorse PSMA PET for primary staging

Indication	Level of evidence	Imaging notes on PSMA PET
Unfavorable intermediate risk	2A	• PSMA PET can be considered for bone and soft tissue full-body imaging and can also be considered for equivocal results on initial bone imaging • Owing to its increased sensitivity and specificity, conventional imaging is not a necessary prerequisite to PSMA PET • PSMA PET can serve as an equally effective, if not more effective, front-line imaging tool compared with conventional imaging in these patients
High-risk	2A	
Very high-risk	2A	

NCCN Clinical Practice Guidelines in Oncology (NCCN Guidelines®), Prostate Cancer, Version 1.2023 — September 16, 2022 NCCN.org

American Urological Association

…. high risk for metastatic disease with negative conventional imaging, clinicians <u>may</u> obtain molecular imaging to evaluate for metastases. (Expert Opinion)

Eastham JA, Auffenberg GB, Barocas DA, et al. Clinically localized prostate cancer: AUA/ASTRO guideline, part I: introduction, risk assessment, staging, and risk-based management. J Urol. 2022;208(1):10-18.

luzerner kantonsspital
KLINIK FÜR UROLOGIE LUZERN

Cleveland Clinic
CLEVELAND CLINIC INNOVATIONS
Celebrate Innovation

#1 Next Generation of mRNA Vaccinology

#2 PSMA-Targeted Therapy in Prostate Cancer