DR. SENCKENBERGISCHES INSTITUT FÜR PATHOLOGIE

UNIVERSITÄTS KLINIKUM FRANKFURT GOETHE-UNIVERSITÄT

Hodgkin Lymphoma

Diagnostic pitfalls and what´s new?

Sylvia Hartmann
Dr. Senckenberg Institut für Pathologie
Frankfurt am Main, Germany

Interessenkonflikt

Es besteht kein Interessenkonflikt.

Special features of Hodgkin Lymphoma?

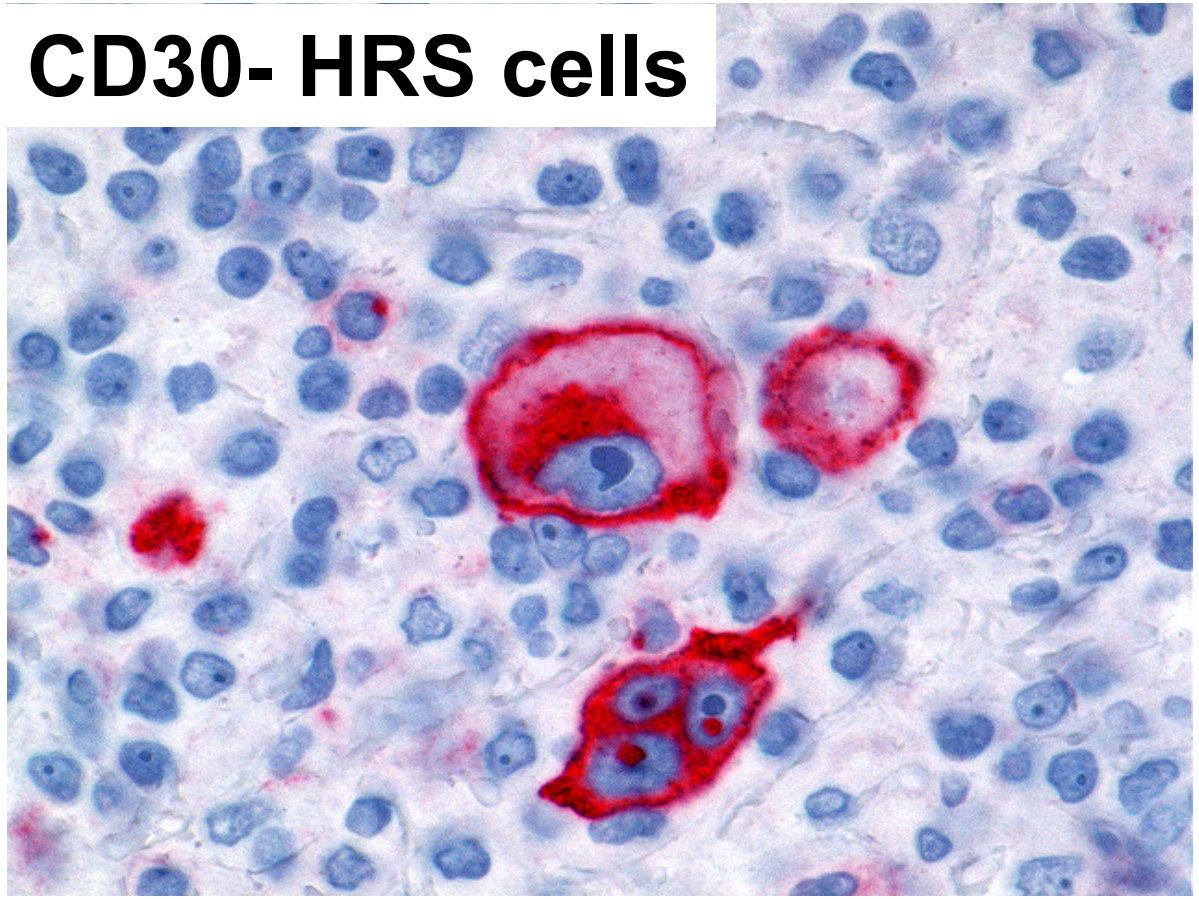

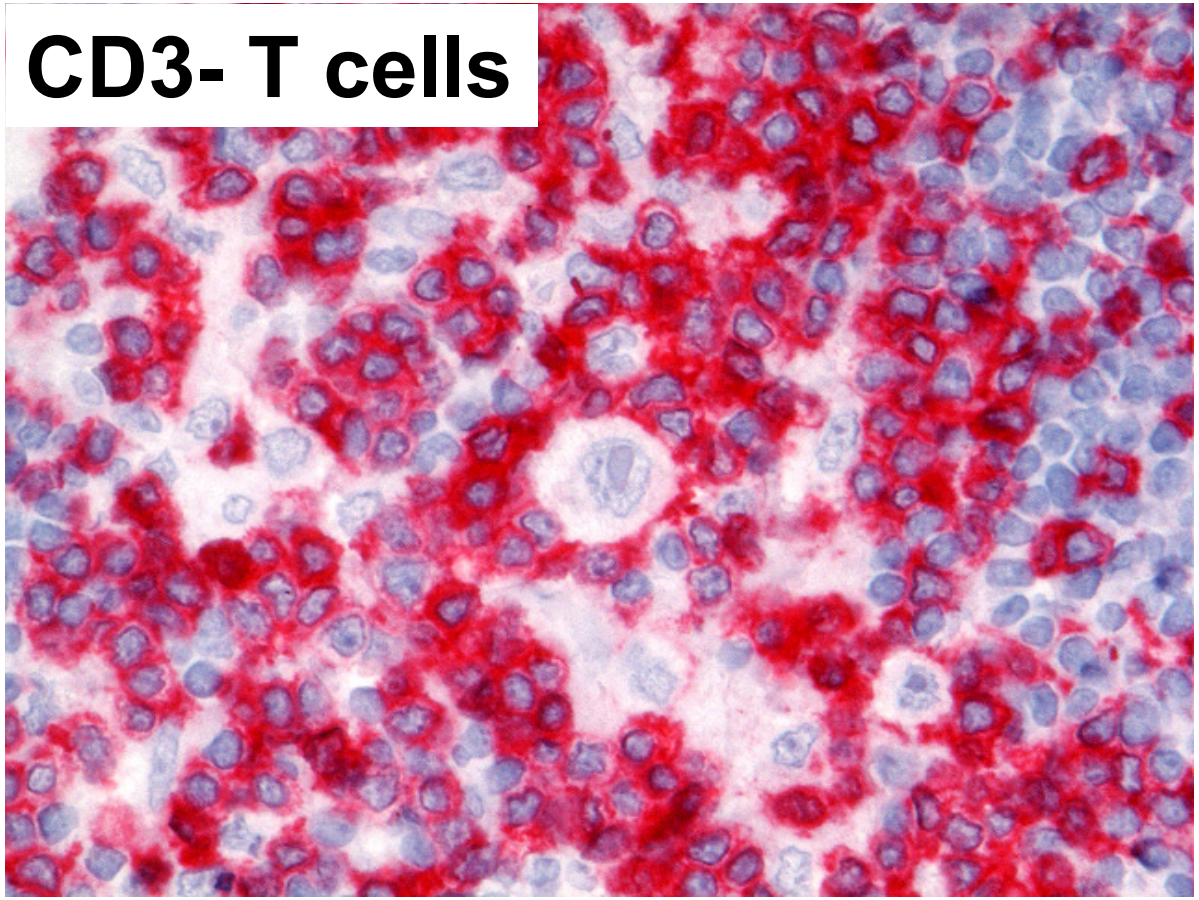

Molecular investigation of cHL on circulating cell free DNA

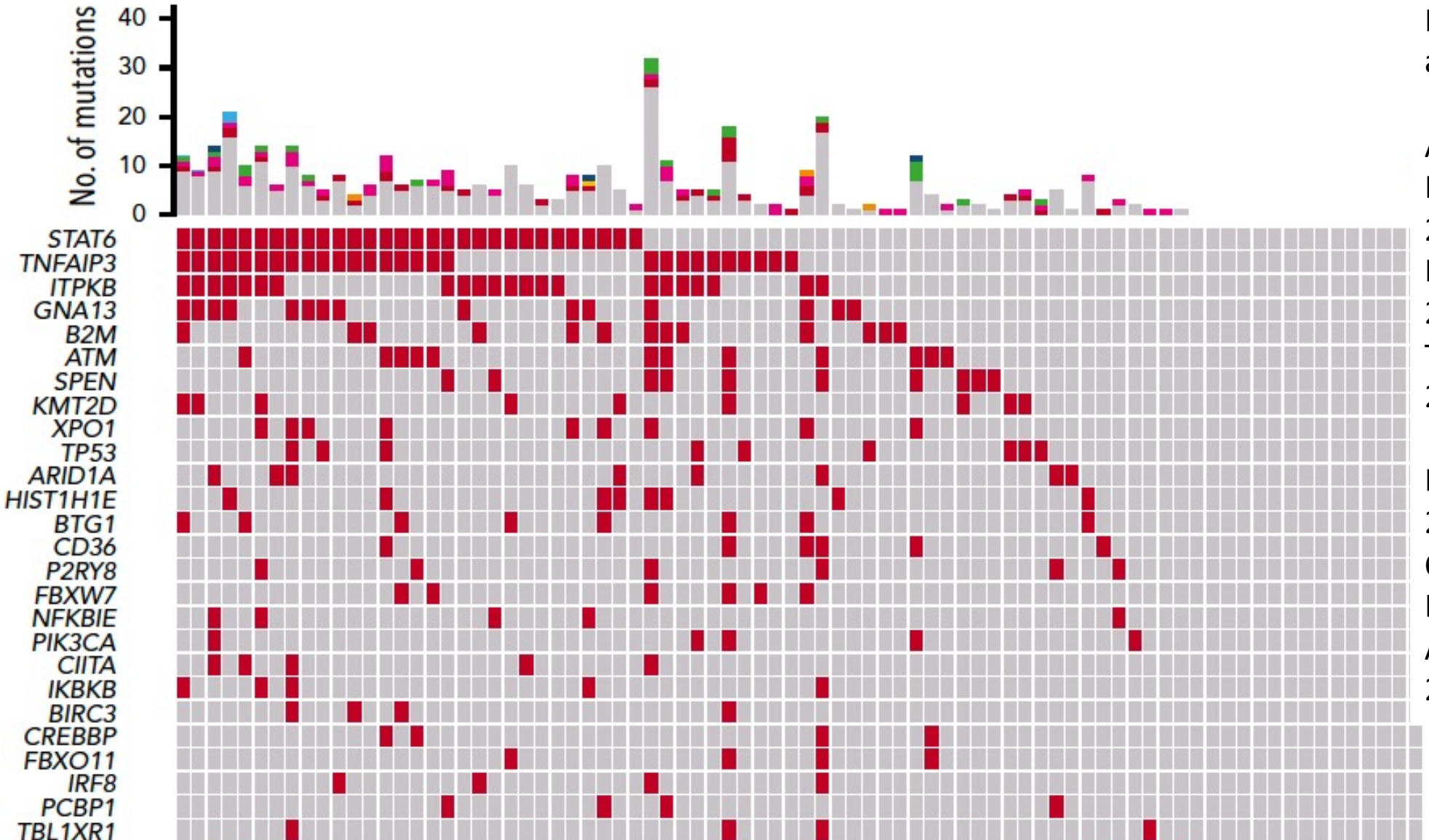

Figure from Spina et al., Blood 2018

And also
Reichel et al., Blood 2015
Mata et al, Oncotarget 2017
Tiacci et al., Blood 2018

Desch et al. Leukemia 2020
Camus et al., Haematologica 2021
Alig et al., Nature 2023

Distribution of Hodgkin types by age

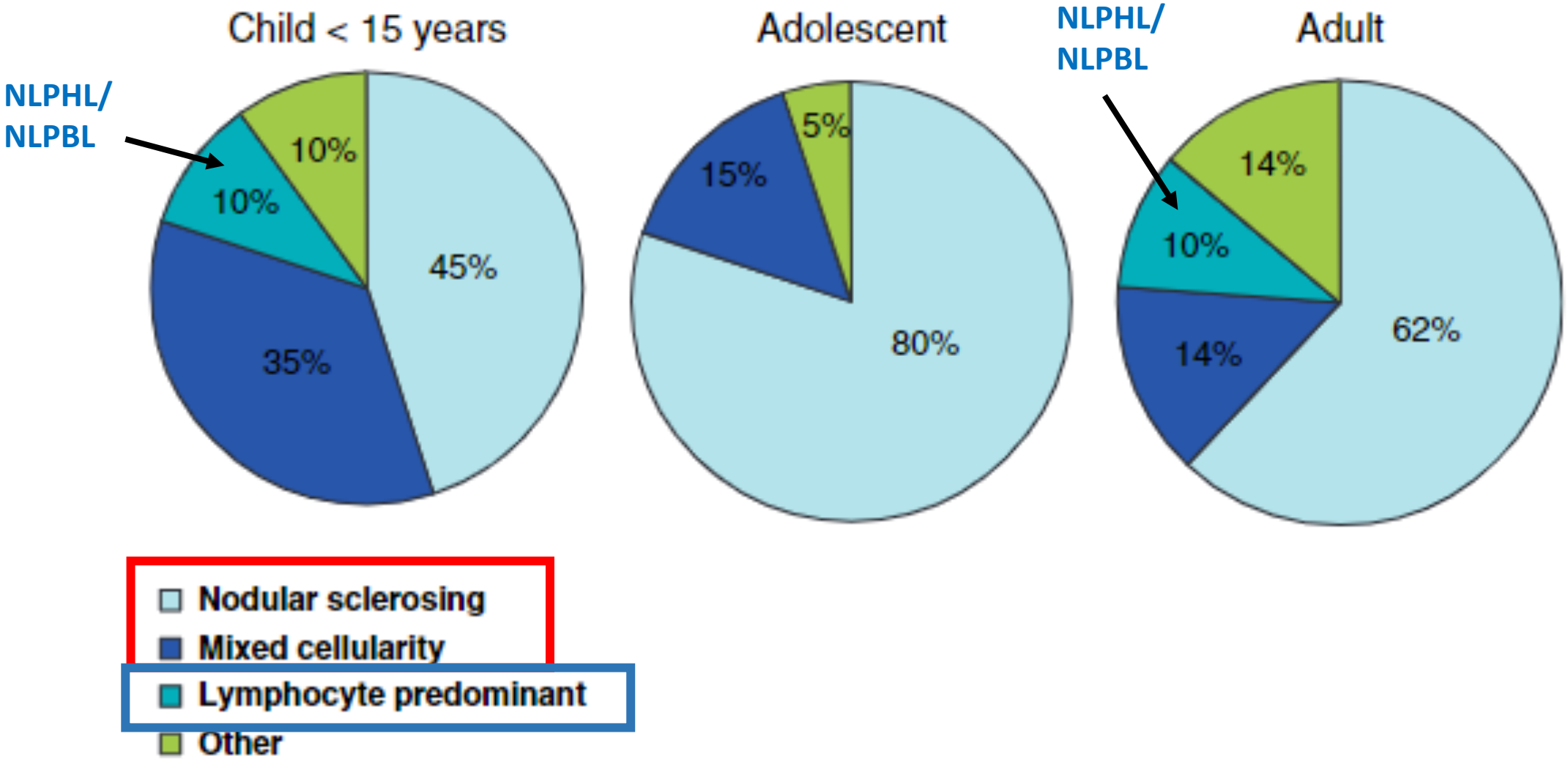

Hochberg *et al.*, Br J Haematol 2008

Hodgkin lymphomas

WHO 5th Edition and ICC:

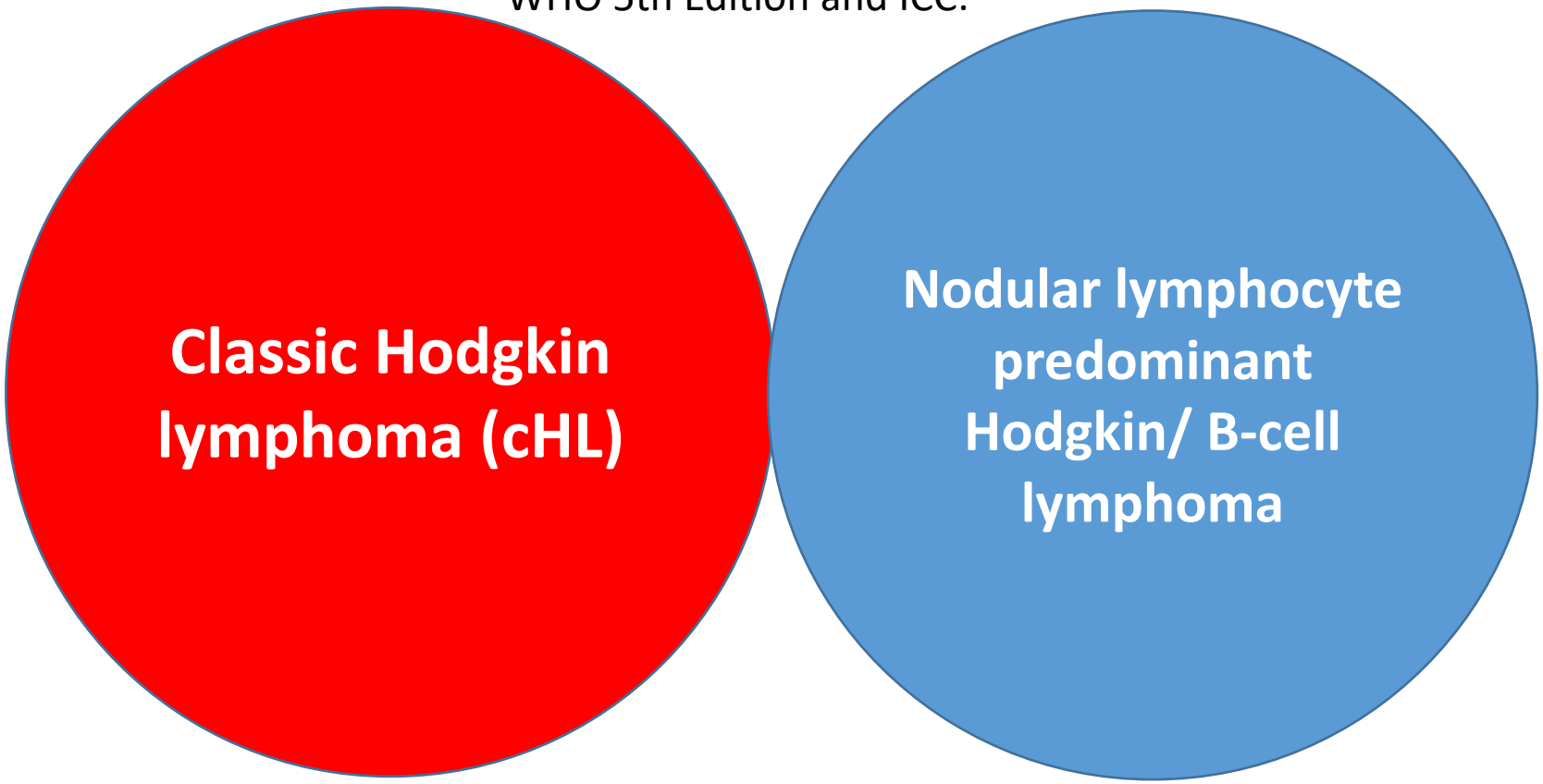

Classic subtypes

- reflect different biology
- do not impact treatment or outcome

Classic HL: Diagnostic criteria by WHO-HAEM5

Essential diagnostic criteria	• **Primary nodal or mediastinal presentation.** • **HRS cells and variants in a reactive microenvironment composed of varying proportions of small lymphocytes, eosinophils, histiocytes, plasma cells and neutrophils.** • **Immunophenotype of HRS cells: CD30+, PAX5+ (weak to moderate), CD20-/ weak/ heterogeneous**
Desirable diagnostic criteria	• **Immunophenotype of HRS cells: CD15+, CD45-, decreased expression of OCT2 and BOB1** • **EBV positive (~40% of cases)** • **Histological subtyping (if possible)** • **Exclusion of mimics of cHL by appropriate work-up.**

Neoplasias with Hodgkin (-like) cells

Formerly



Nowadays: ICC and WHO classifications

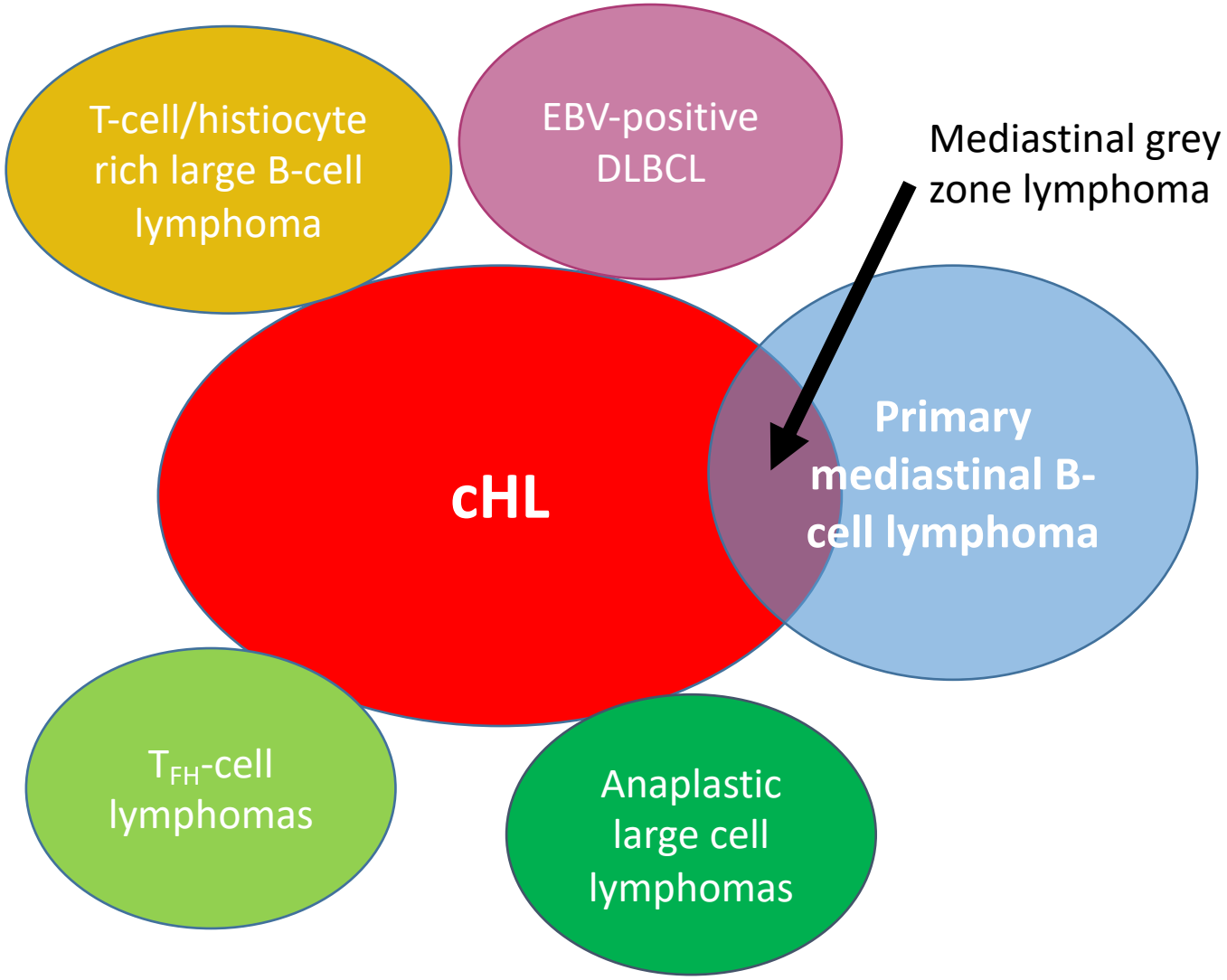

Neoplasias with Hodgkin (-like) cells

Formerly



Nowadays: ICC and WHO classifications

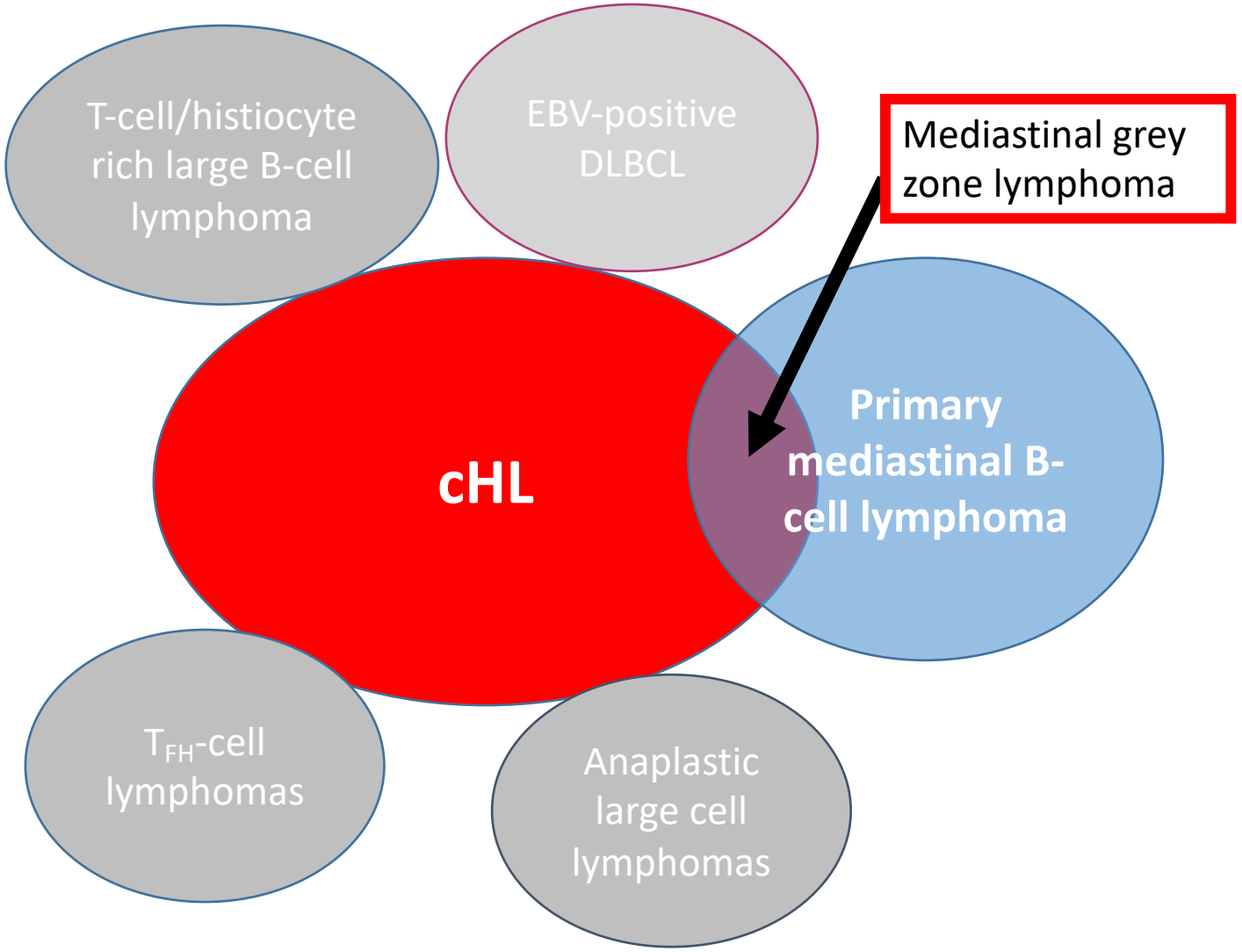

Mediastinal grey zone lymphomas
Sarkozy et al., Blood 2021

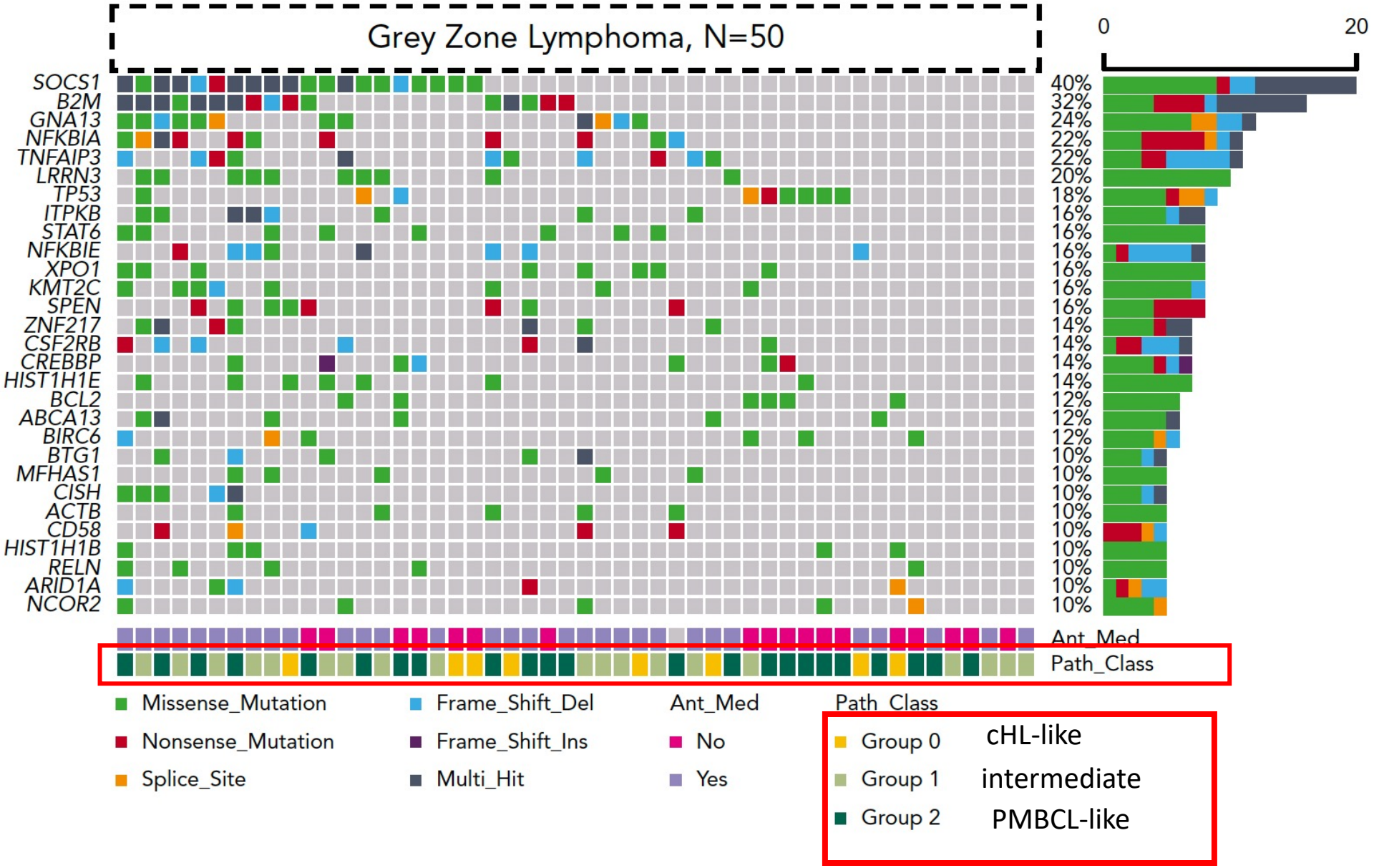

Sarkozy et al., Haematologica 2017
Sarkozy et al., Am J Surg Path 2019
Sarkozy et al., Blood Adv 2020
Sarkozy et al., Blood 2021

Mediastinal grey zone lymphoma (MGZL)

MGZL CHL-like according to WHO HAEM-5

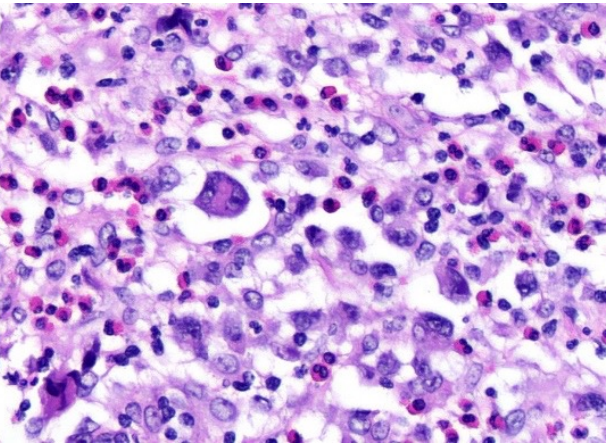

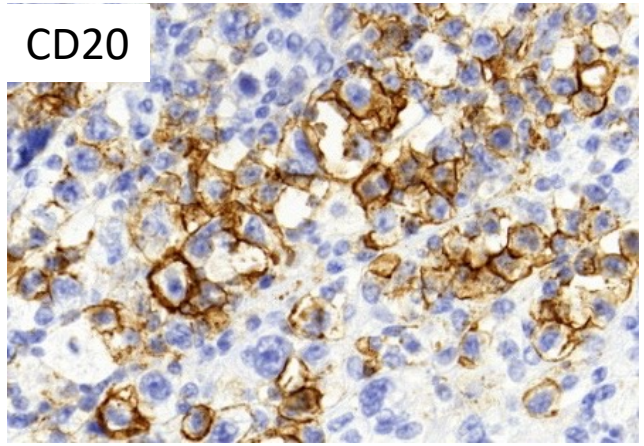

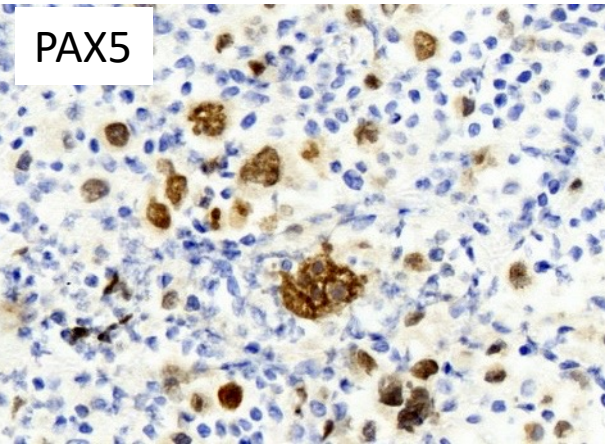

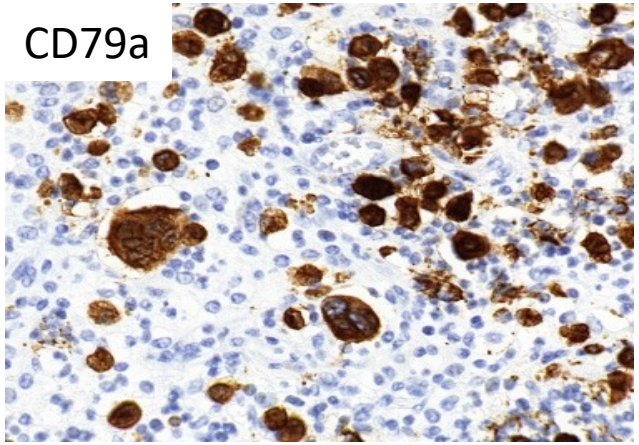

MGZL PMBL-like according to WHO HAEM-5

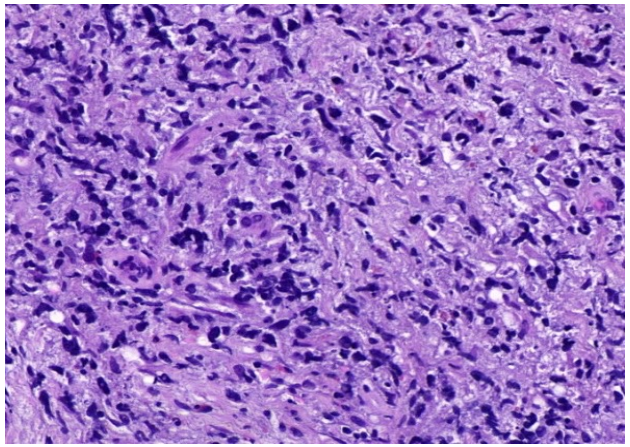

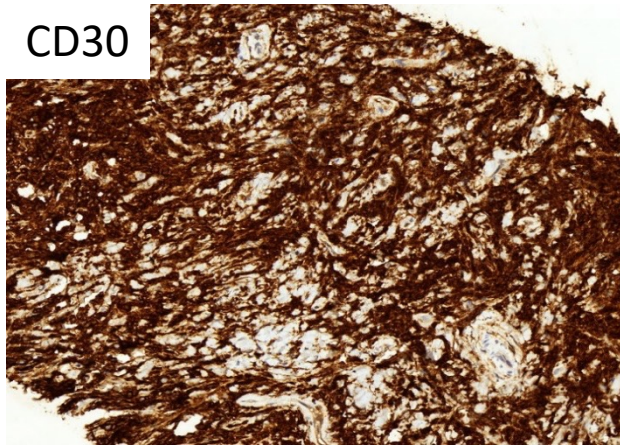

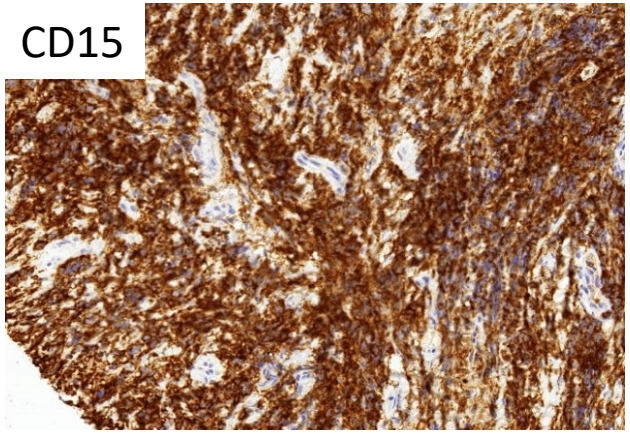

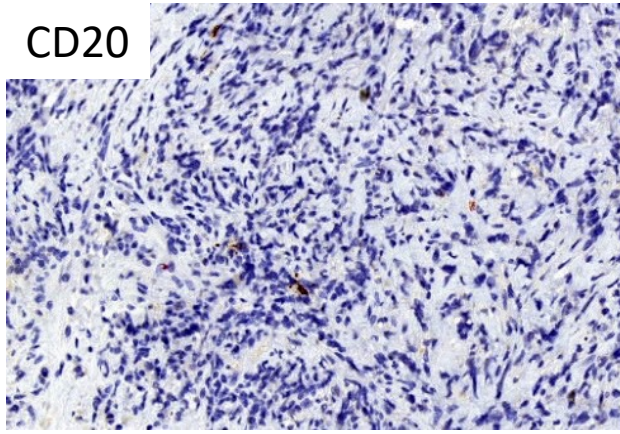

Mediastinal grey zone lymphoma (MGZL)

MGZL CHL-like according to WHO HAEM-5

- Confluent growth of pleomorphic cells and abundant microenvironment
- Uniform strong expression of CD20 AND uniform strong PAX5 AND uniform and strong expression of at least one additional B-cell marker (CD19, CD79a, BOB1, OCT2)
- CD30 expression

MGZL PMBL-like according to WHO HAEM-5

- Monomorphic sheets of neoplastic cells
- CD30 strong and partial or complete loss of B-cell markers OR strong CD15 expression

ICC:

≥ 2 B-cell markers with strong expression

EBV-positive diffuse large B-cell lymphoma

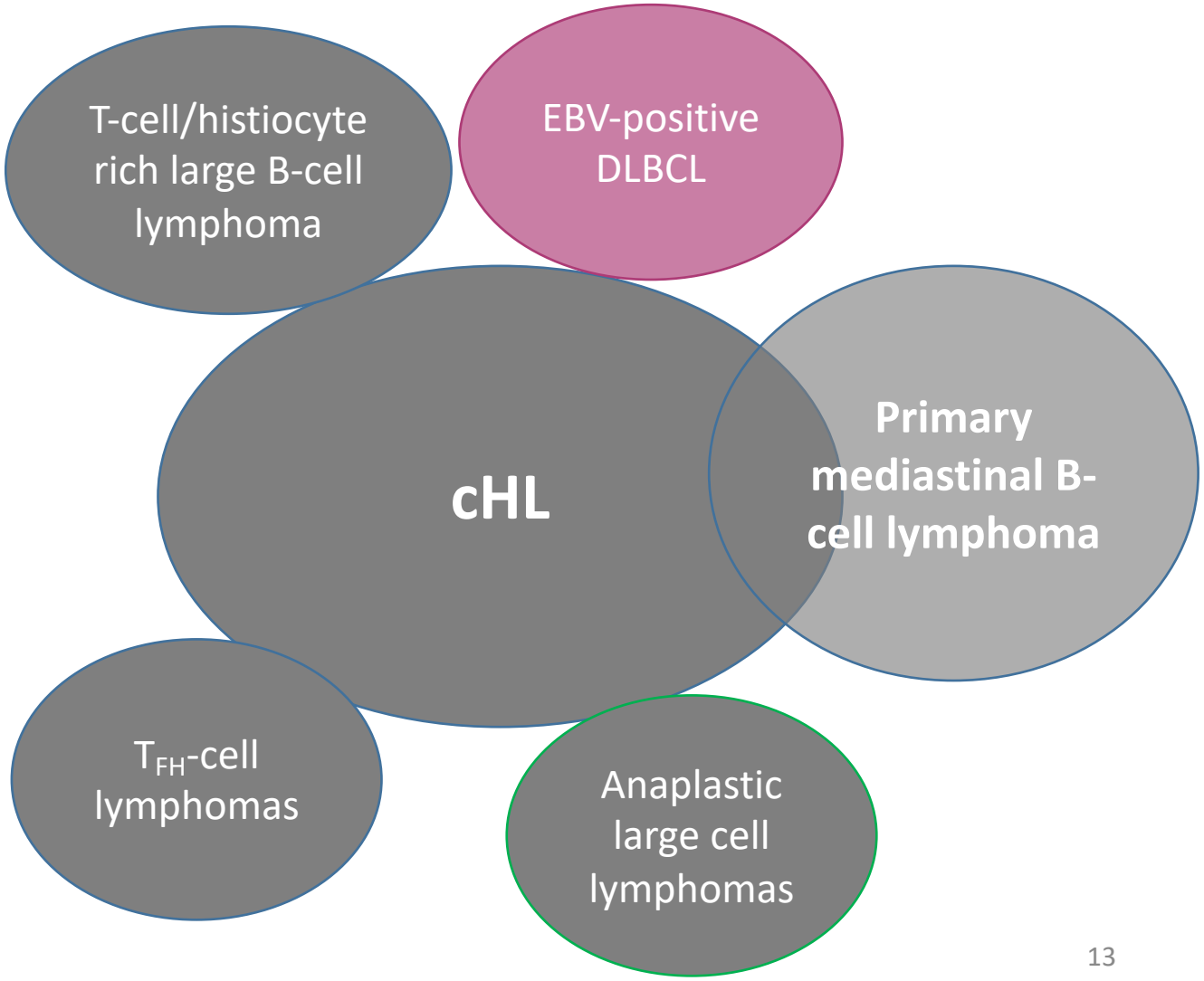

Case. 64 year-old male. Clinical suspicion of oropharynx cancer and cervical lymph node metastasis

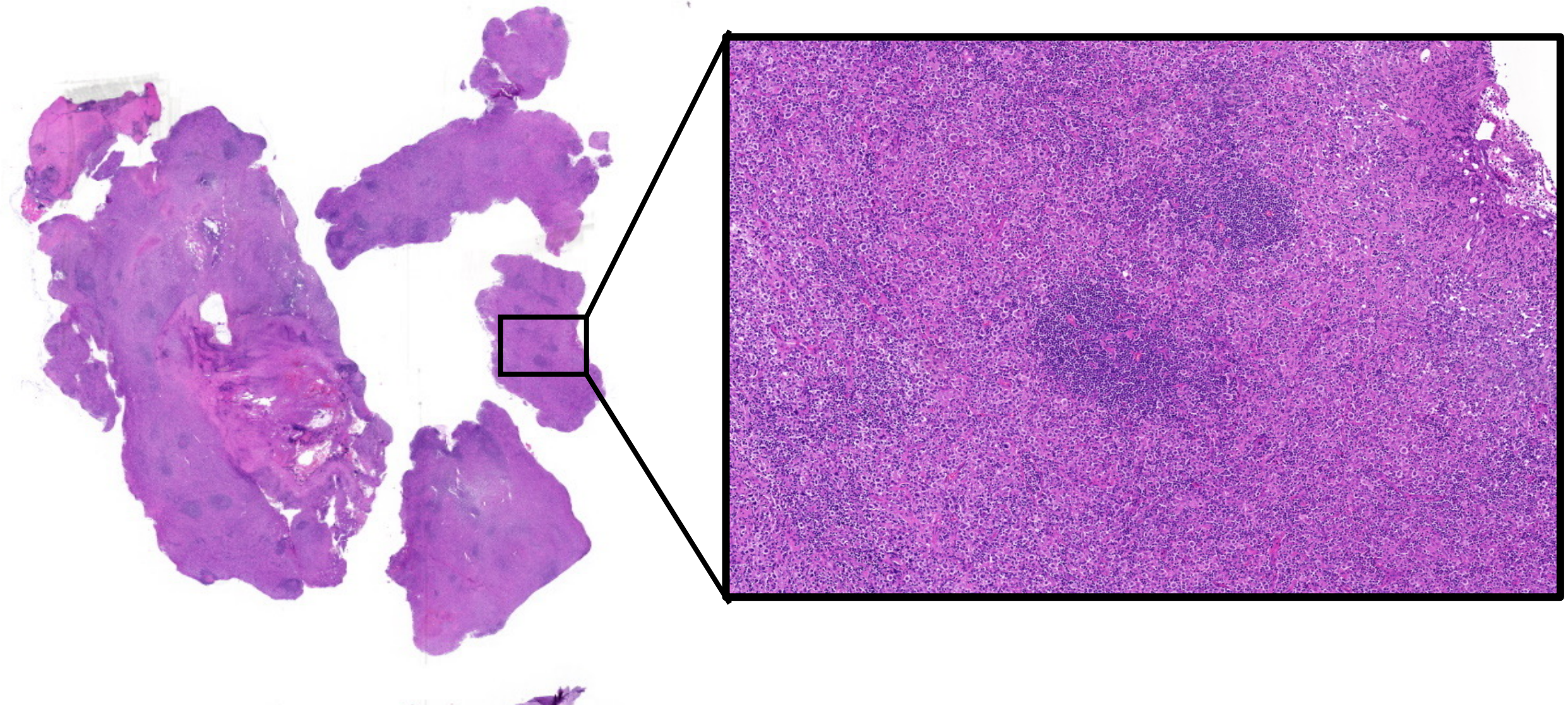

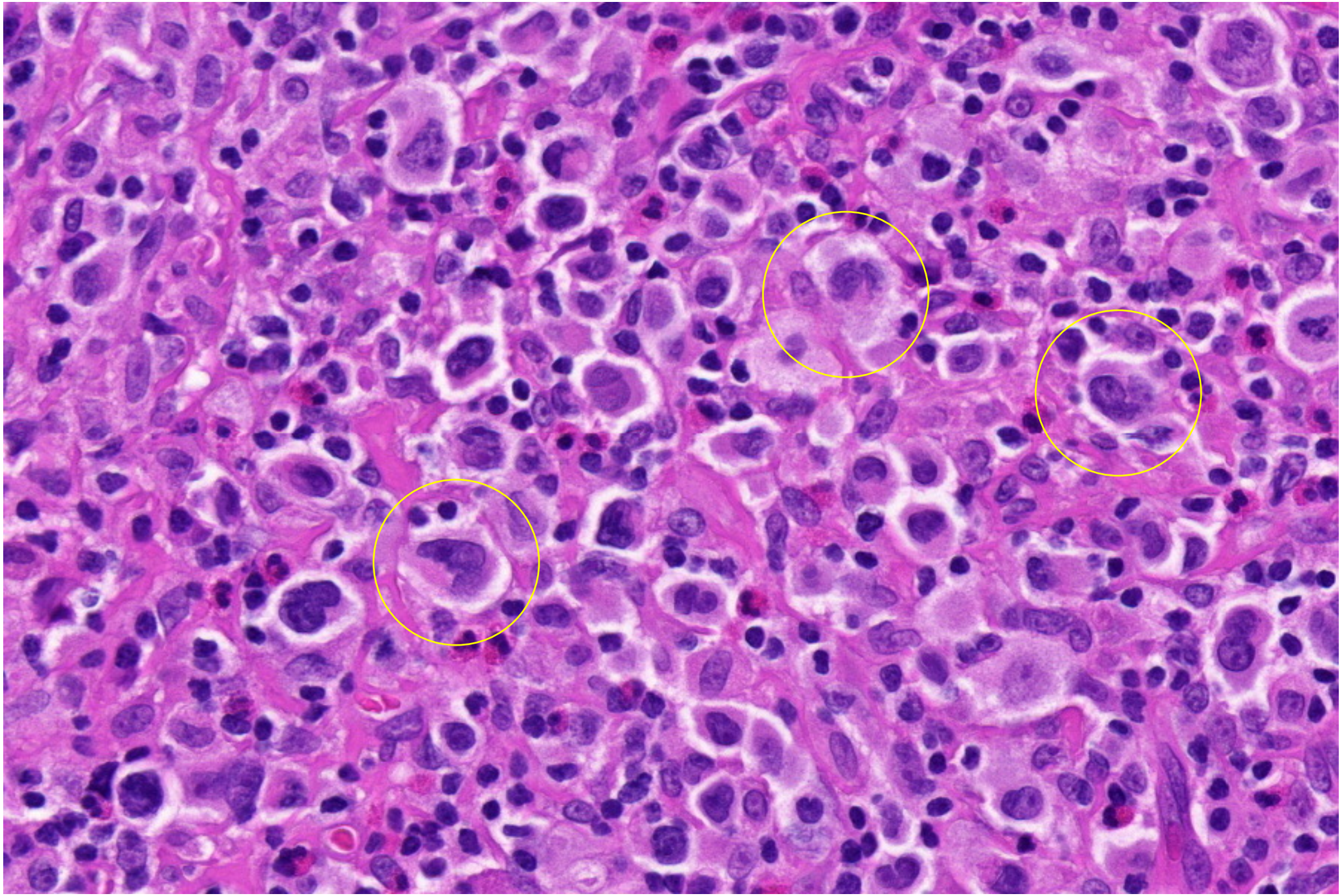

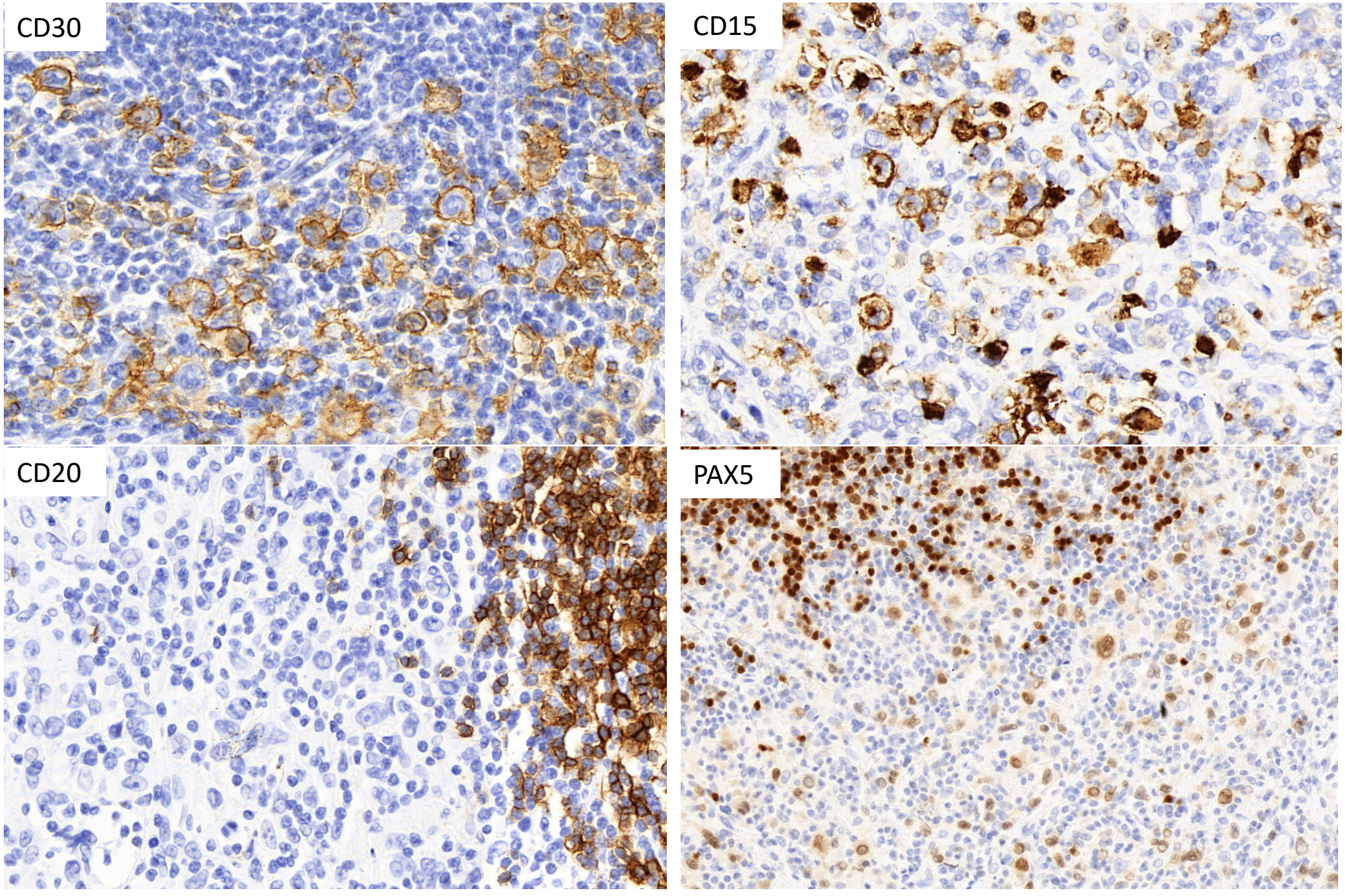
CD30
CD15
CD20
PAX5

Biopsy of „oropharynx cancer“

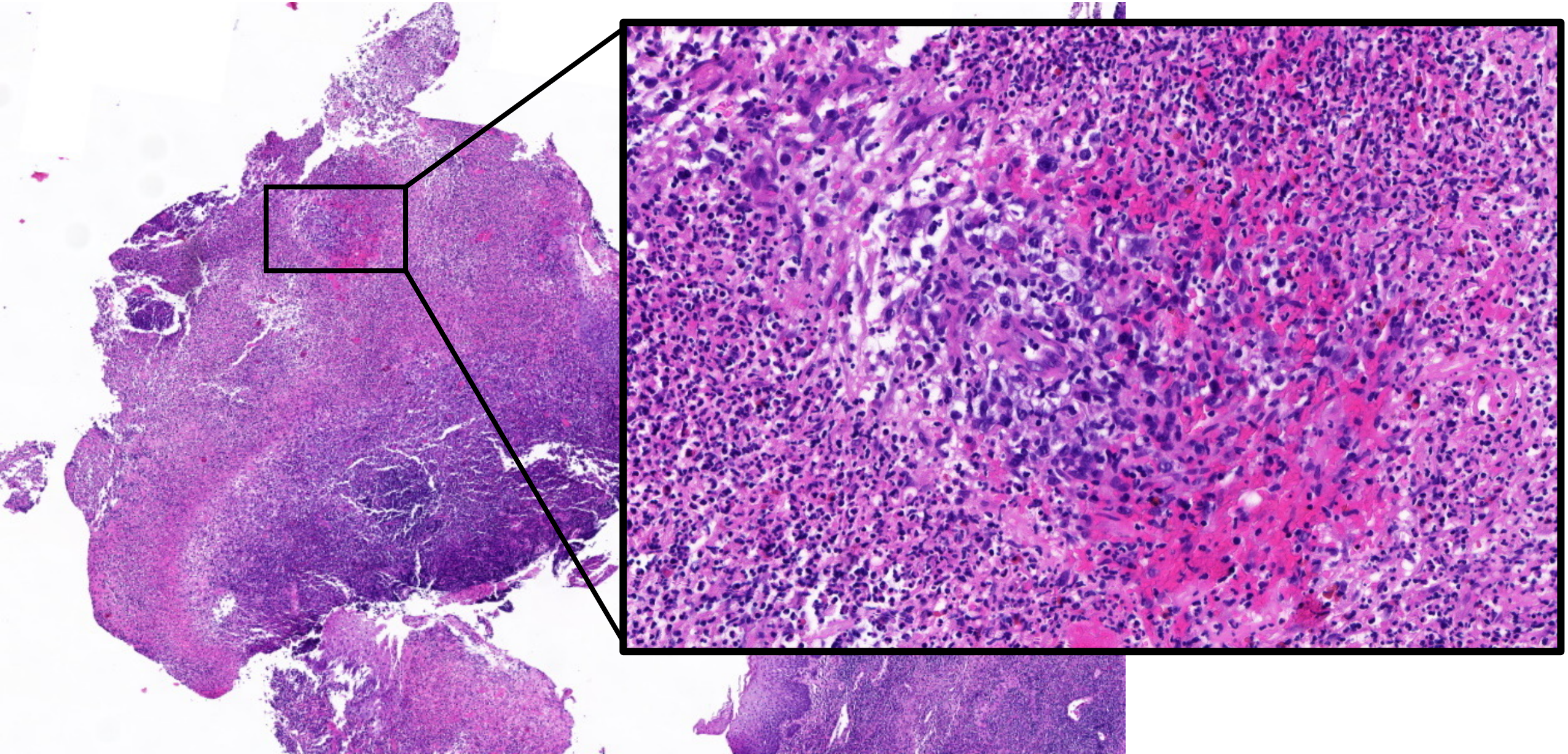

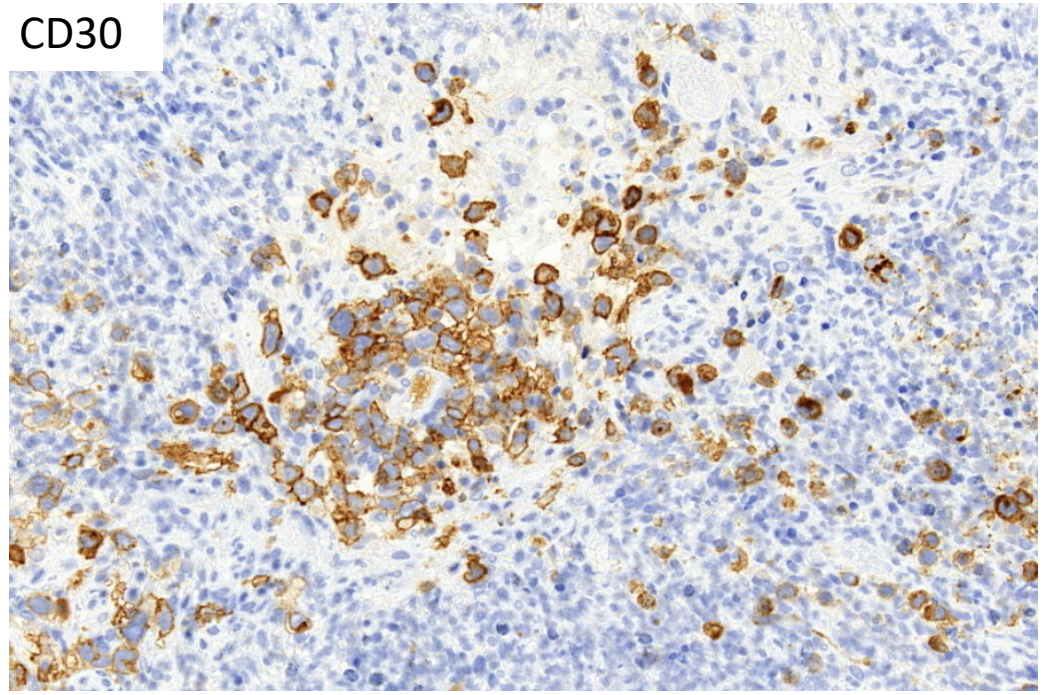
CD30

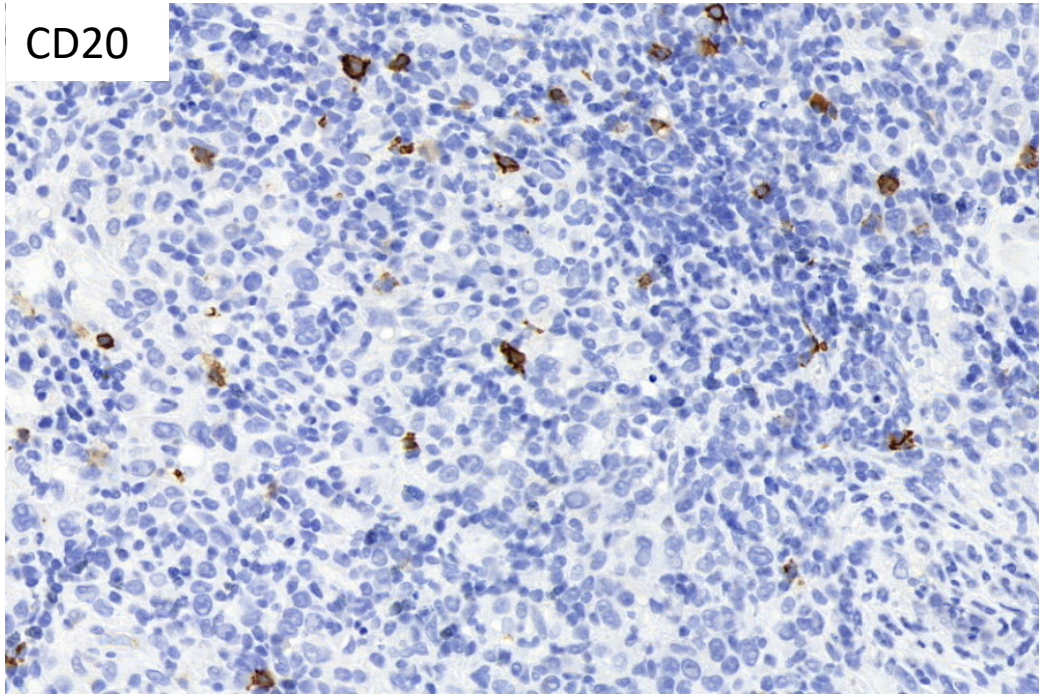
CD20

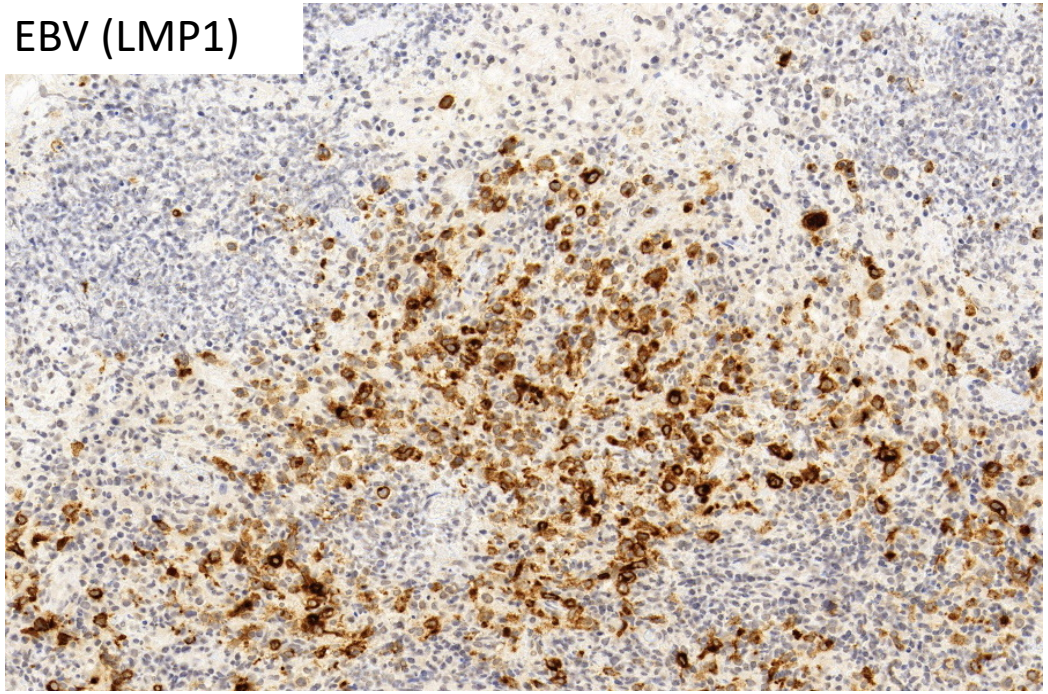
EBV (LMP1)

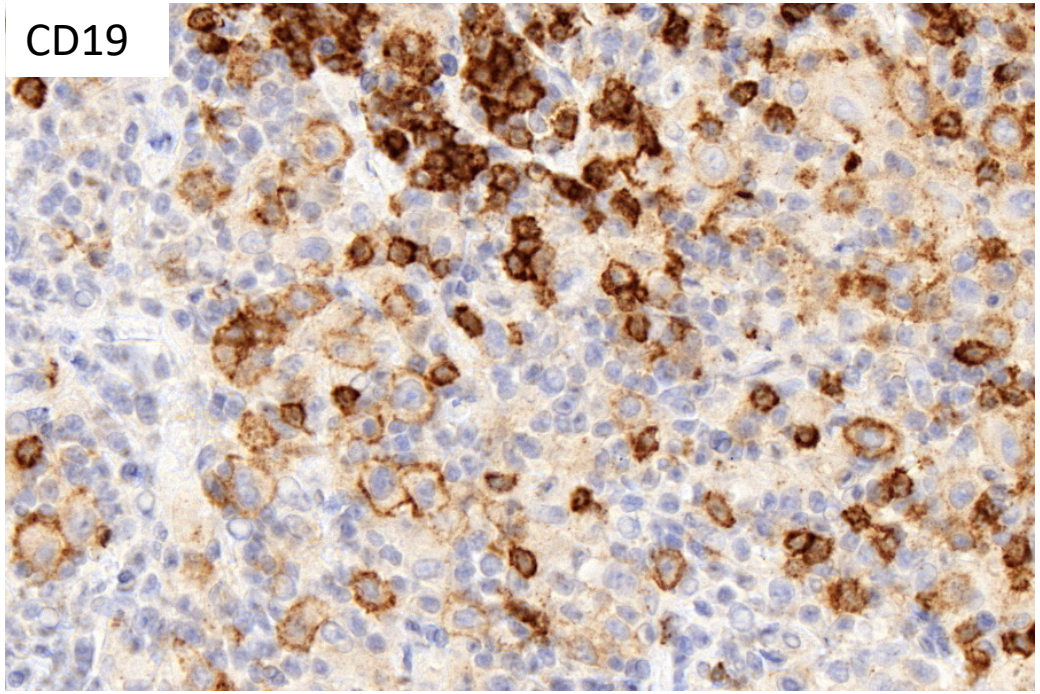
CD19

EBV-positive diffuse large B-cell lymphoma (with extranodal involvement)

Differential diagnosis to cHL, mixed cellularity:

- **Morphology slightly different**
- **Immunophenotype similar**
- **Expression of B-cell markers in >50% of the tumor cells**
- **Clinical information (extranodal presentation) is crucial!**
- **EBV latency III**

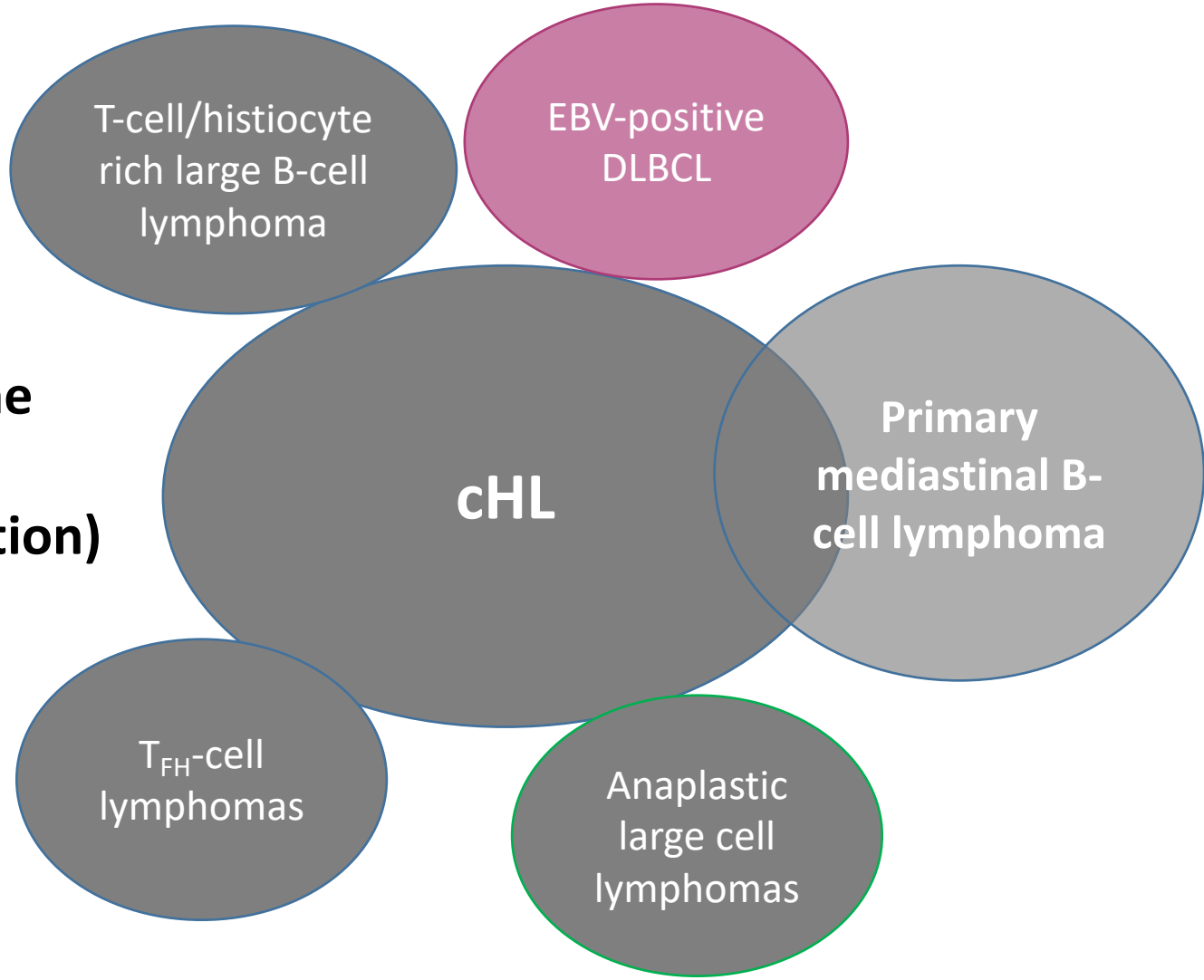

Park et al., Blood 2007
Nicolae et al., Blood 2015
Bourbon et al., Blood Adv 2021
EBVMCU:
Dojcinov et al., Am J Surg Path 2010

T-cell/histiocyte rich large B-cell lymphoma

THRLBCL

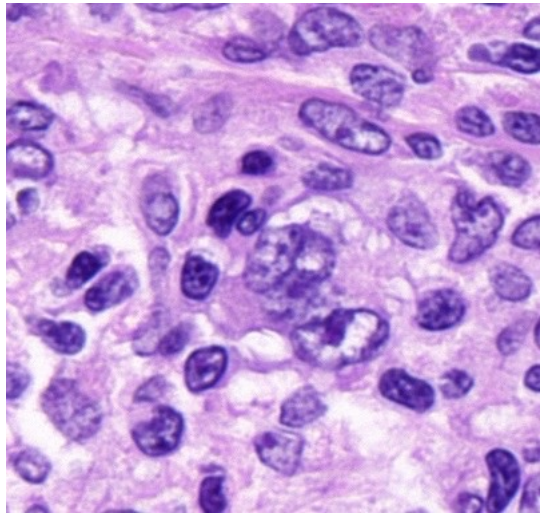

cHL

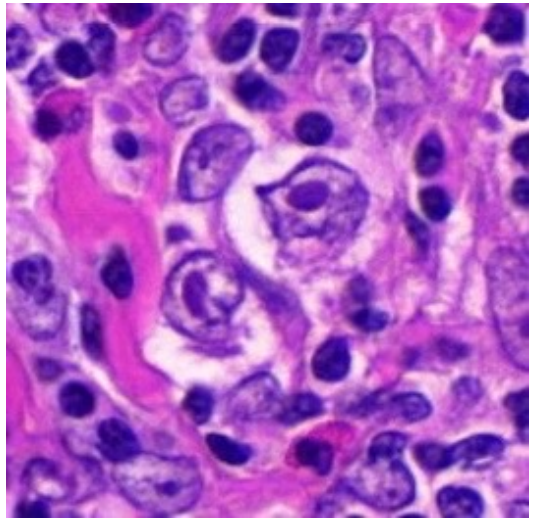

	HRS cells of cHL	Tumor cells of THRLBCL
CD20	**- (weak)**	**+**
CD79a	**-**	**+**
BCL6	**-**	**+**
CD30	**+**	**-**
OCT2	**+**	**-**
EBV	**+/-**	**-**

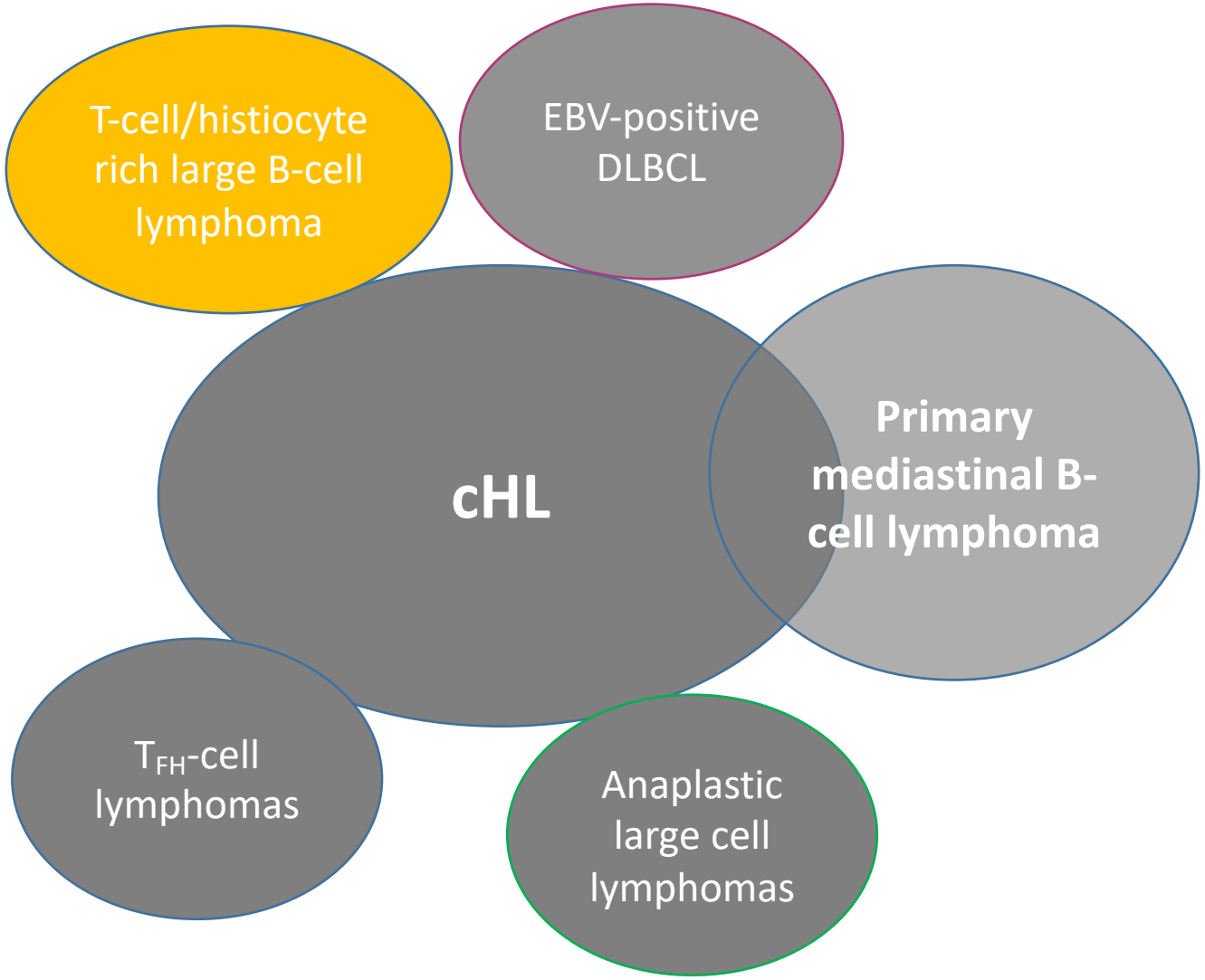

T_{FH}-cell lymphomas with HRS-like cells

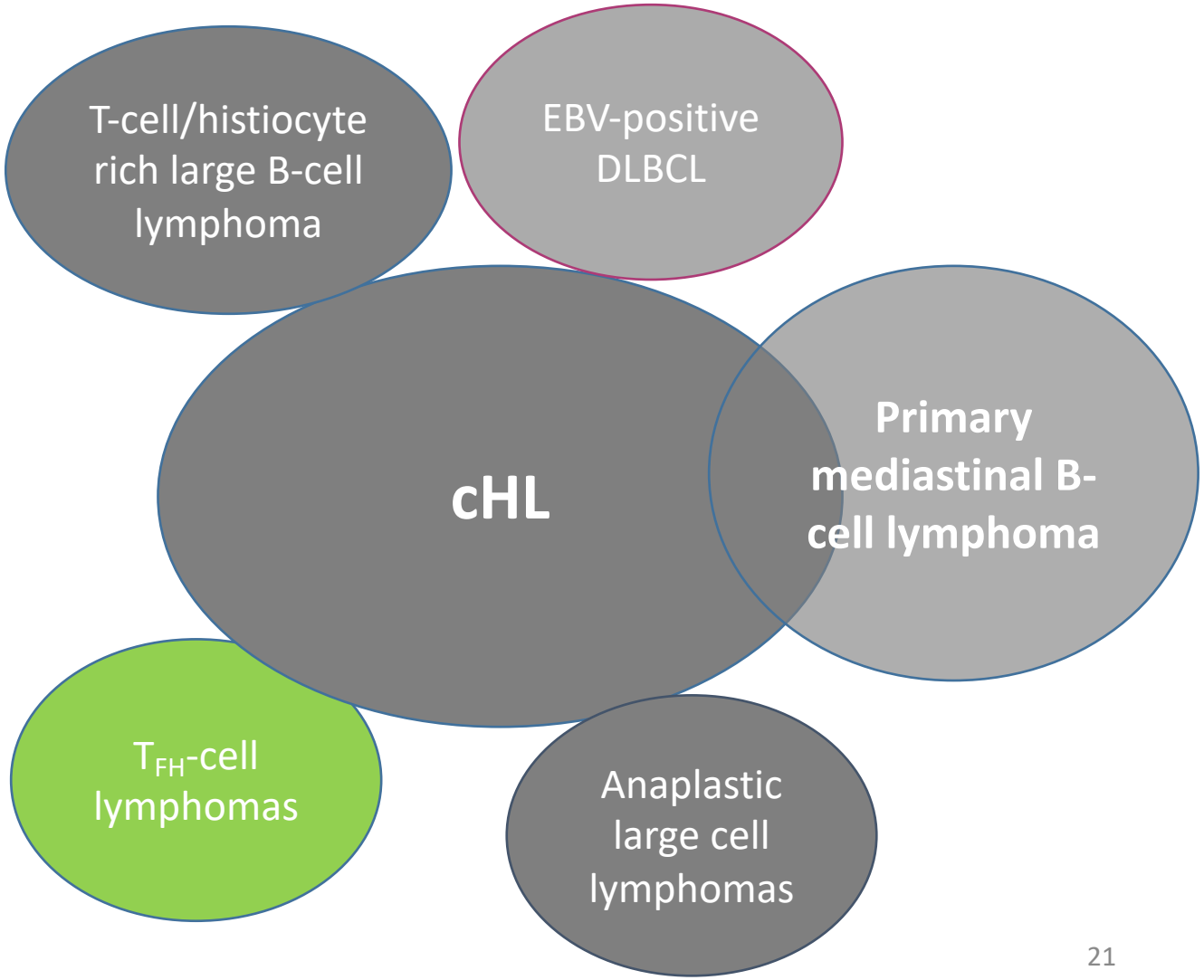

T_{FH} cell lymphomas with Hodgkin-like cells

PD1

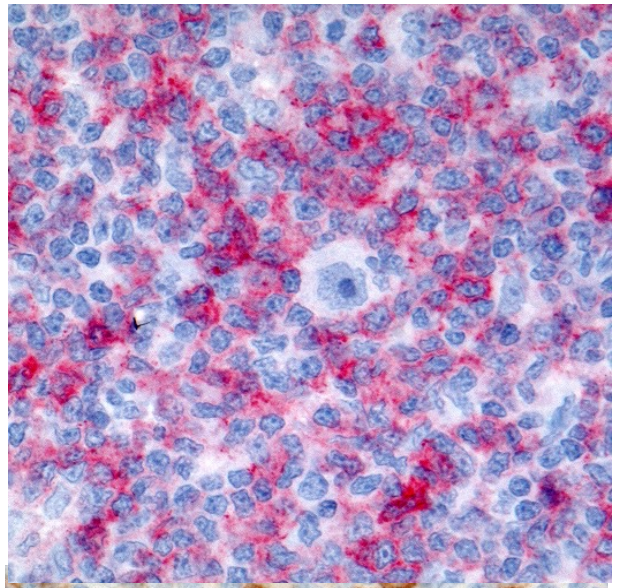

CD10

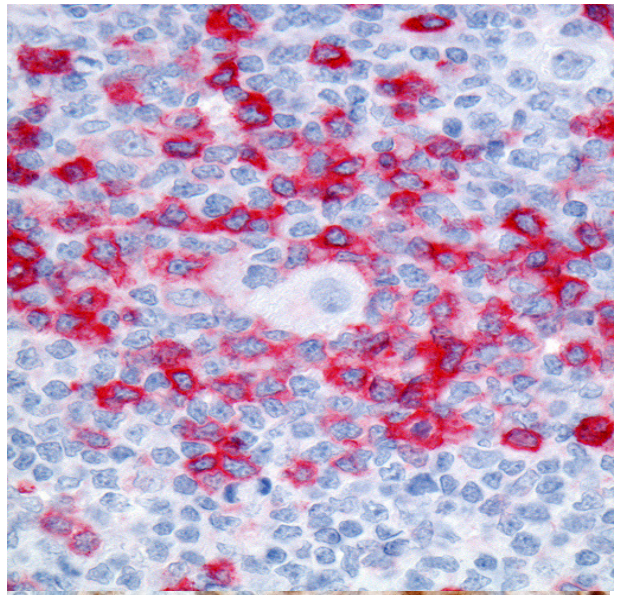

ICOS

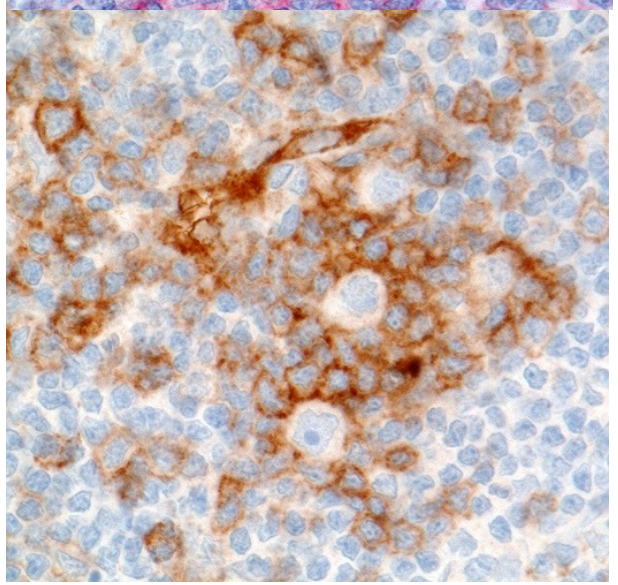

CXCL13

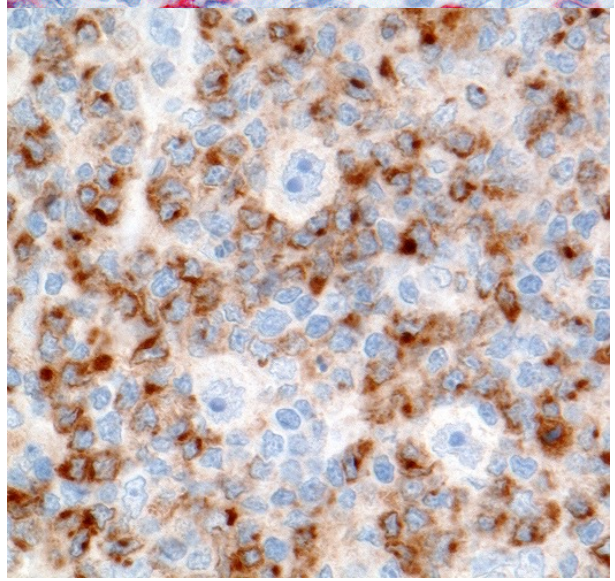

Quintanilla et al., Am J Surg Path 1999

Agostinelli et al., Histopathology 2011

Moroch et al., Am J Surg Path 2012

Hodgkin-like cells in T-cell lymphomas

Nodal T-follicular helper cell lymphoma (AITL/NOS/follicular type)

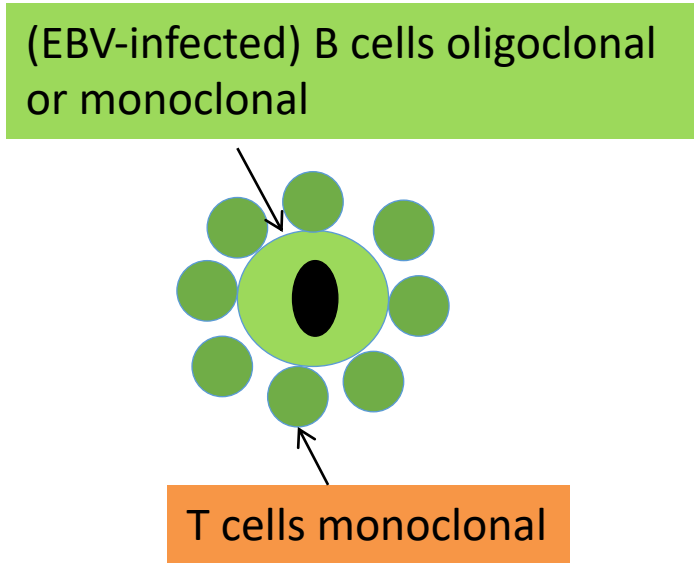

Clonal TCR gene rearrangement and/or RHOA p.G17V or IDH2 p.R172

Quintanilla-Martinez et al., Am J Surg Path 1999
Moroch et al., Am J Surg Path 2012

Hodgkin-Reed-Sternberg cells in cHL

Classical Hodgkin lymphoma

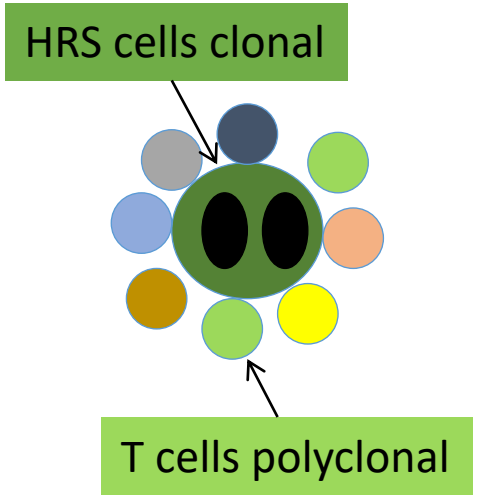

CD30 expression in T_{FH}-cell lymphoma, follicular type

cHL

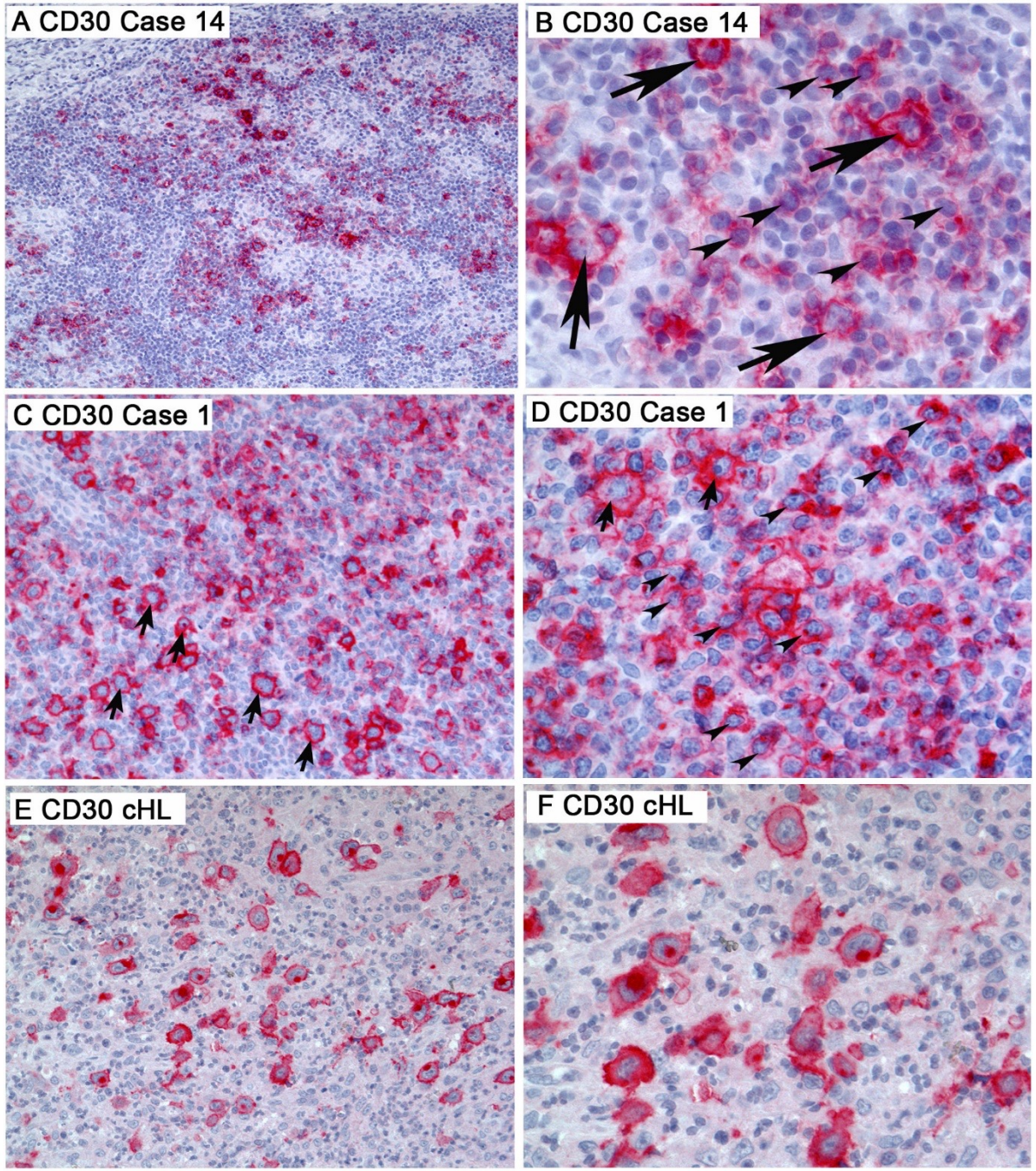

Hartmann et al., Mod Pathol 2019

Differential diagnosis

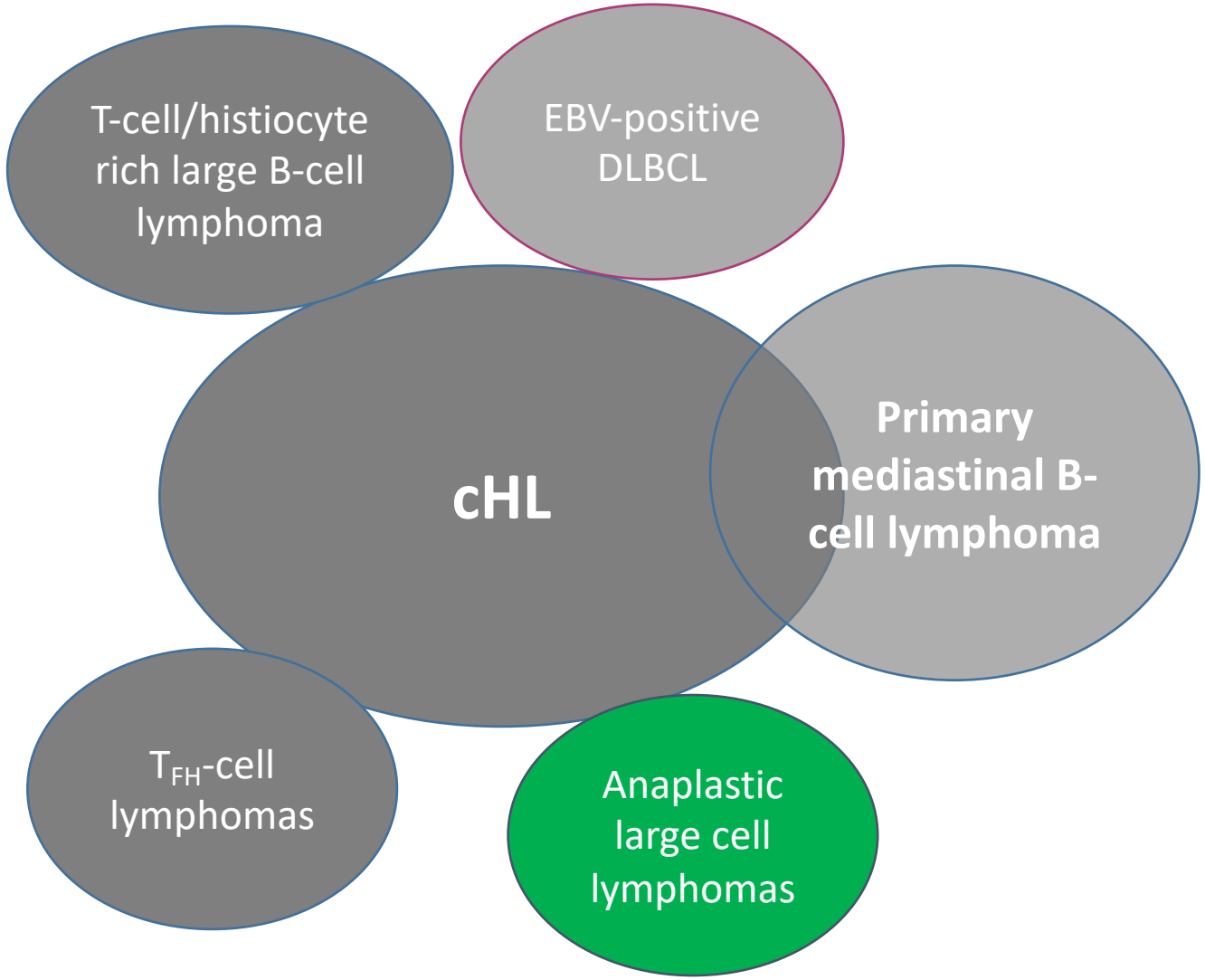

ALK- anaplastic large cell lymphoma

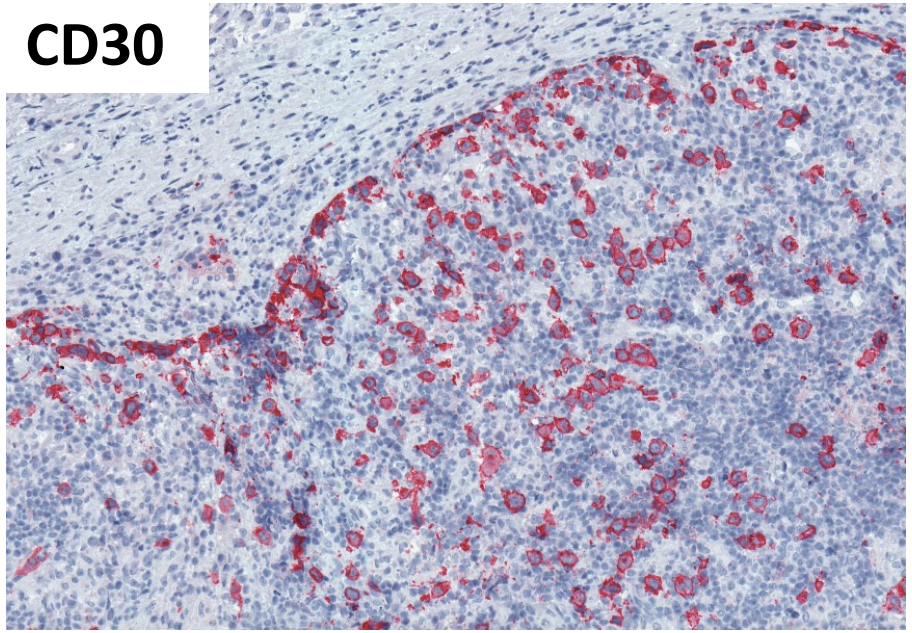

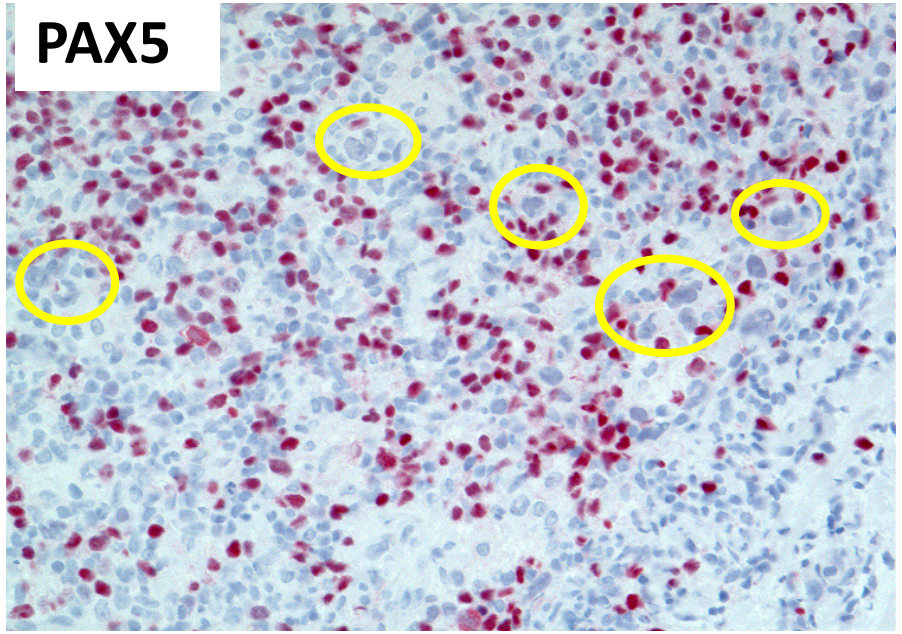

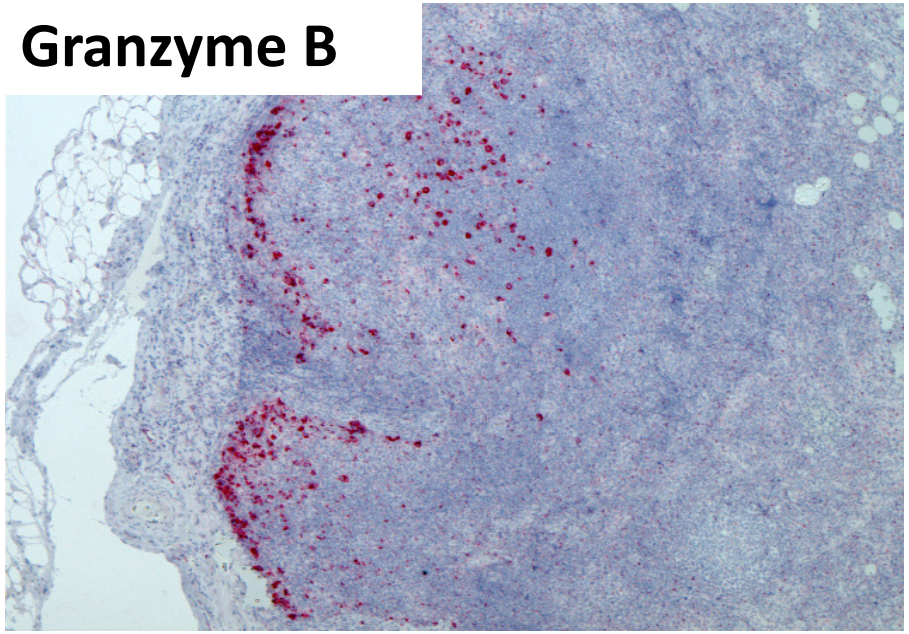

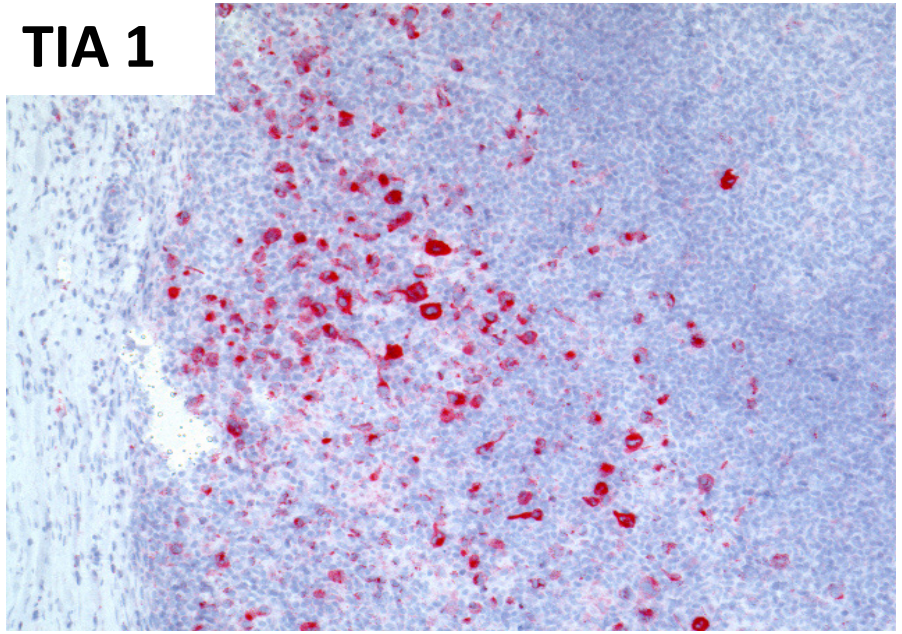

Asano et al.,
Haematologica 2011

Eberle et al.,
Am J Surg Pathol 2012

Crescenzo et al.,
Cancer Cell 2015:
JAK1 and STAT3

ALCL cell lines move faster than cHL cell lines



cHL cell lines



ALCL cell lines

Goncharova *et al.,* Cancers 2019; Bein *et al.* J Cell Mol Med 2022

Neoplasias with Hodgkin (-like) cells

Nowadays: ICC and WHO classifications

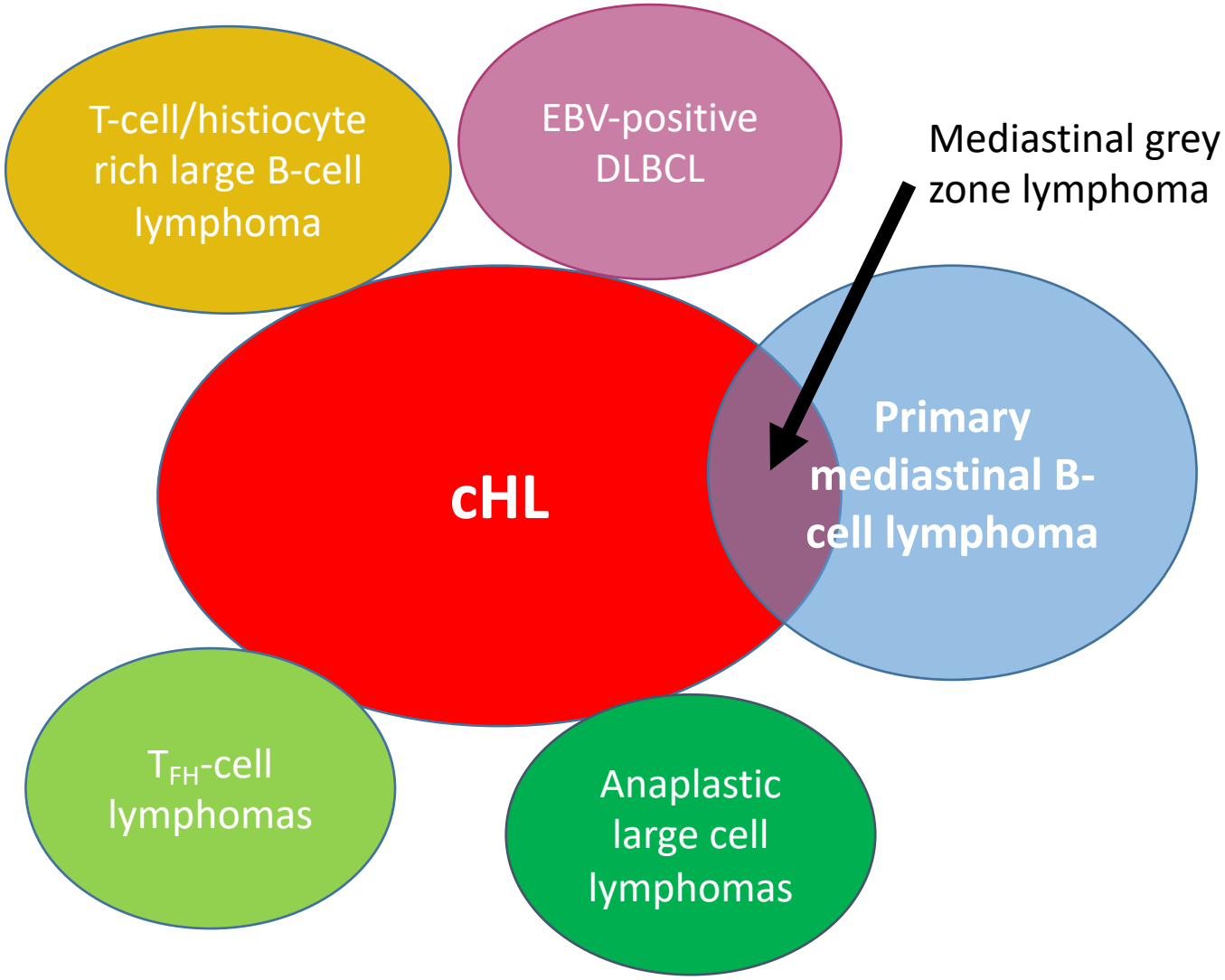

NLPHL/NLPBL in Classifications

	WHO 5th Edition – HAEM-5	International Consensus Classification
Name	NLPHL, alternatively NLPBL can be used	NLPBL
Category	**Hodgkin lymphoma** (category within B-cell lymphoid proliferations and lymphomas)	**Mature B-cell neoplasms** Listed in category Large B-cell lymphoma together with THRLBCL
Variant growth patterns	Indication of Fan* patterns A-F is requested	grading system with grade I (including patterns A-C) and grade II (including patterns D-F) is suggested

* Fan et al., Am J Surg Pathol 2003

Six histopathological growth patterns of NLPHL

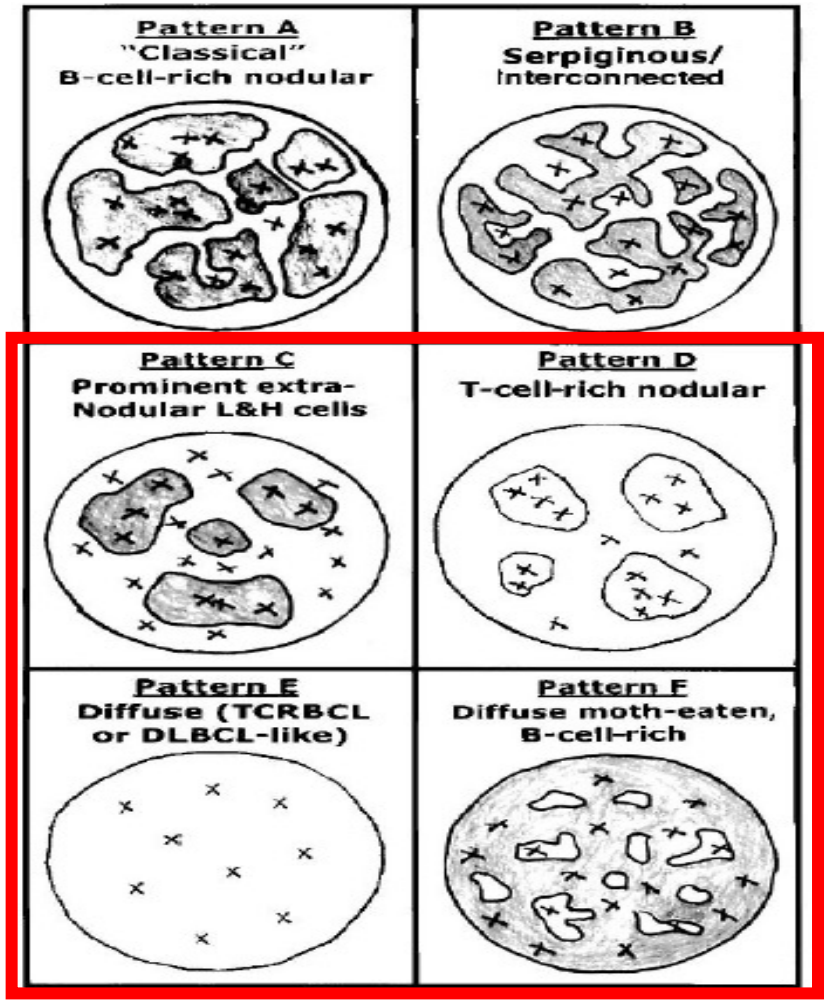

typical

variant

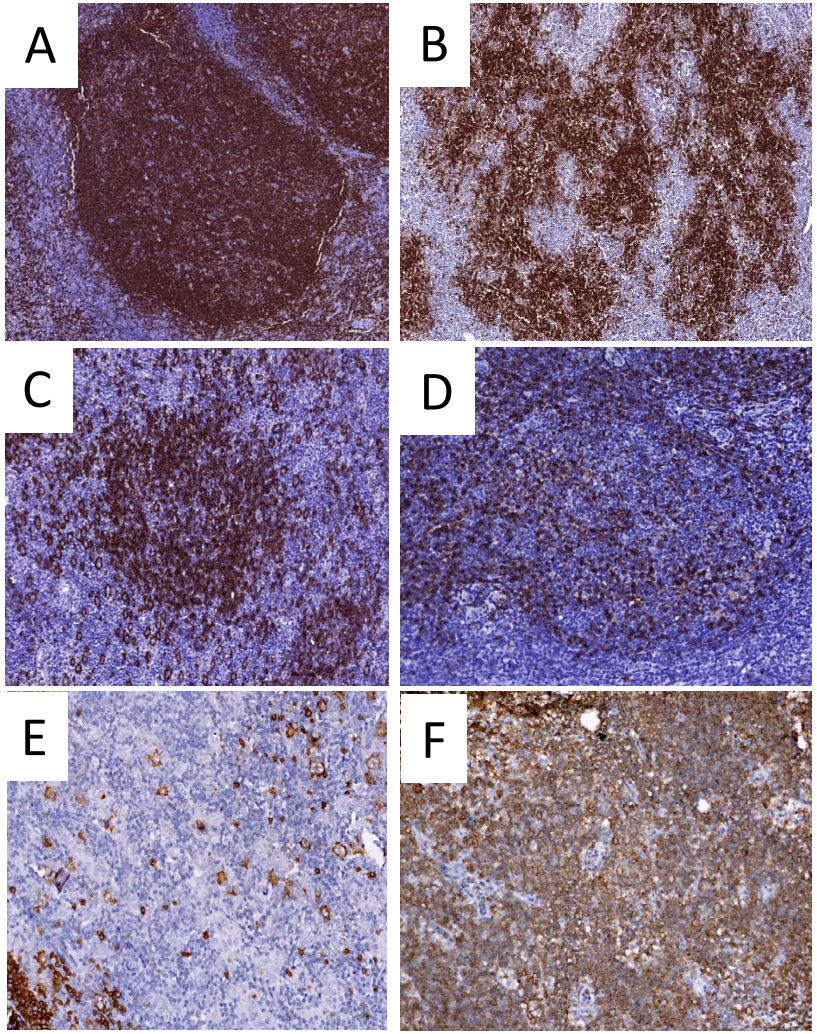

Fan patterns A/B vs. C/D/E/F:

Hartmann et al., Blood 2013
Shankar et al., Br J Haematol 2015

Zhen Fan, MD, Yasodha Natkunam, MD, PhD, Eric Bair, BS, MS, Robert Tibshirani, PhD, and Roger A. Warnke, MD

(*Am J Surg Pathol* 2003;27:1346–1356)

Stage distribution in 151 adult NLPHL patients from the GHSG

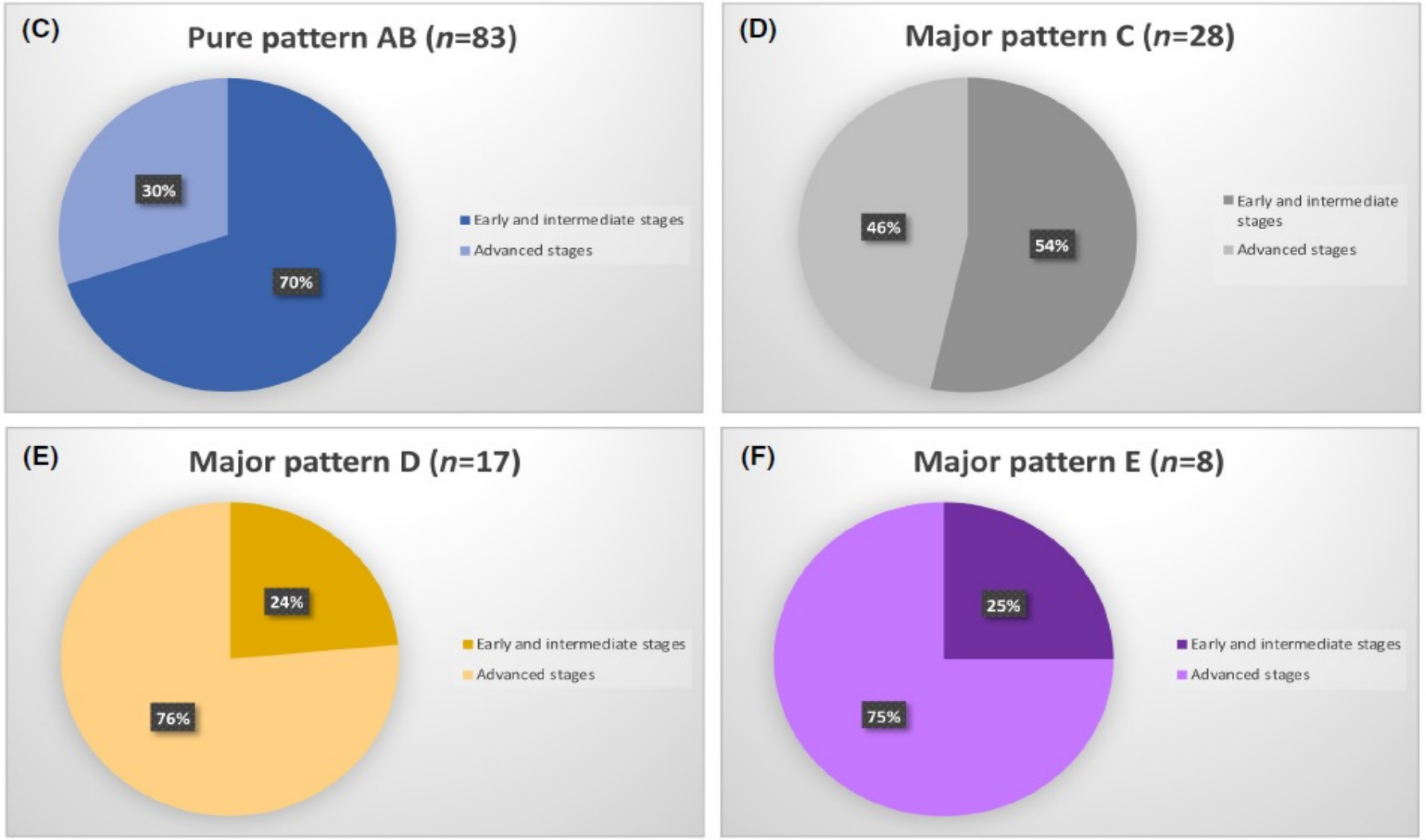

Hartmann et al., Br J Haematol 2022

Patient groups

	cHL	NLPHL/NLPBL	DLBCL
Median age	25-37 y, > 60 y	39 y	66-70 y
Localization	Supradiaphragmatic Lns, > 60% mediastinal	40% cervical and axillary, 20% inguinal and iliacal	Nodal, extranodal in 30-40%
M : F	1.2 : 1	3 : 1	1.5 : 1



Hodgkin?

Pro

ımann et al.,
Oncol 2019,
Classification
M-5

Eichenauer et al.,
JCO 2019,
WHO Classification
HAEM-5

Smith et al., Cancer
epidemiol 2015, SEER
database

NLPHL/NLPBL is a curable disease in most patients

cHL	NLPHL/NLPBL	DLBCL

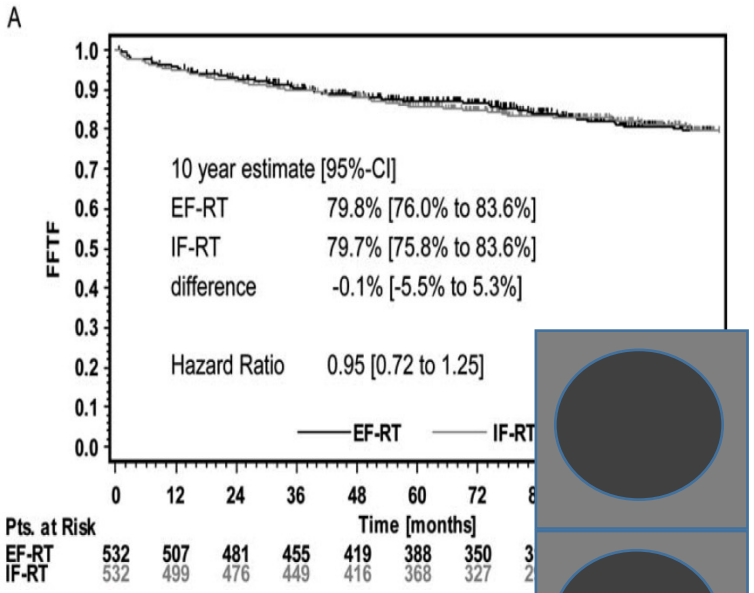



Sasse et al., Ann Oncol 20

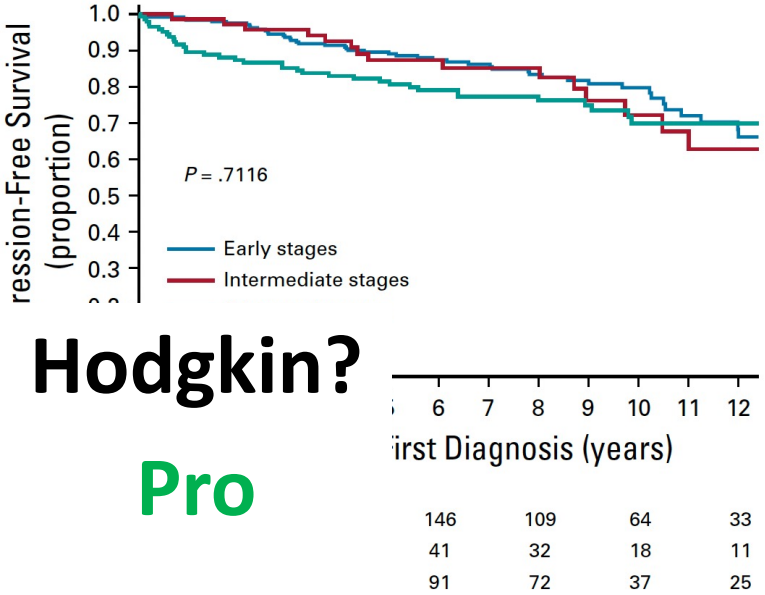

Hodgkin?

Pro

al., JCO 2019

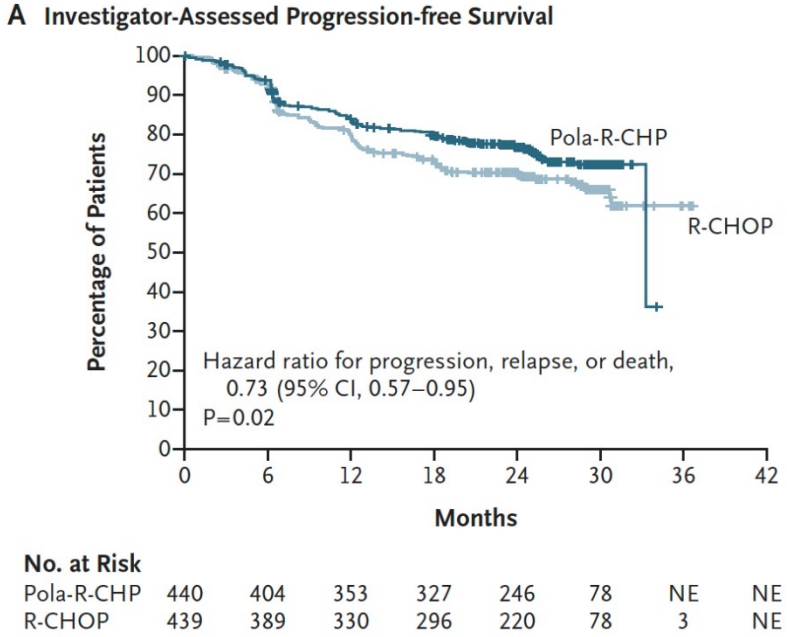

Tilly et al., NEJM 2021

HE Morphology

cHL	NLPHL/NLPBL	DLBCL

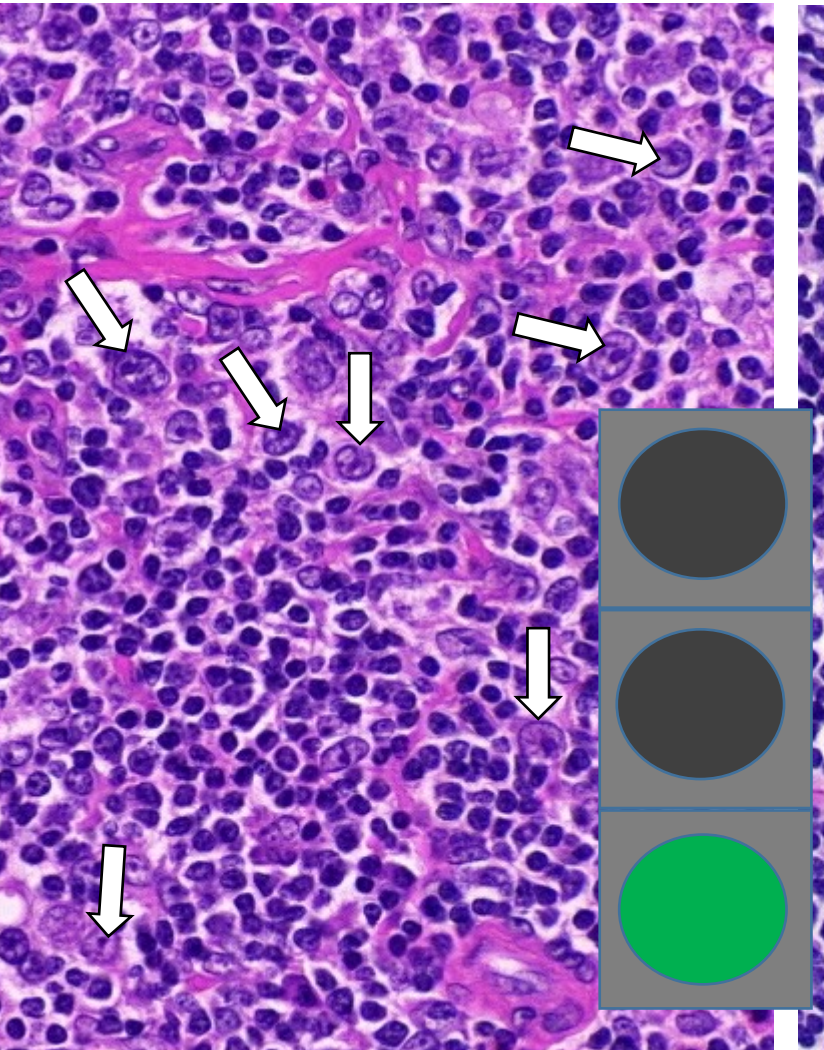

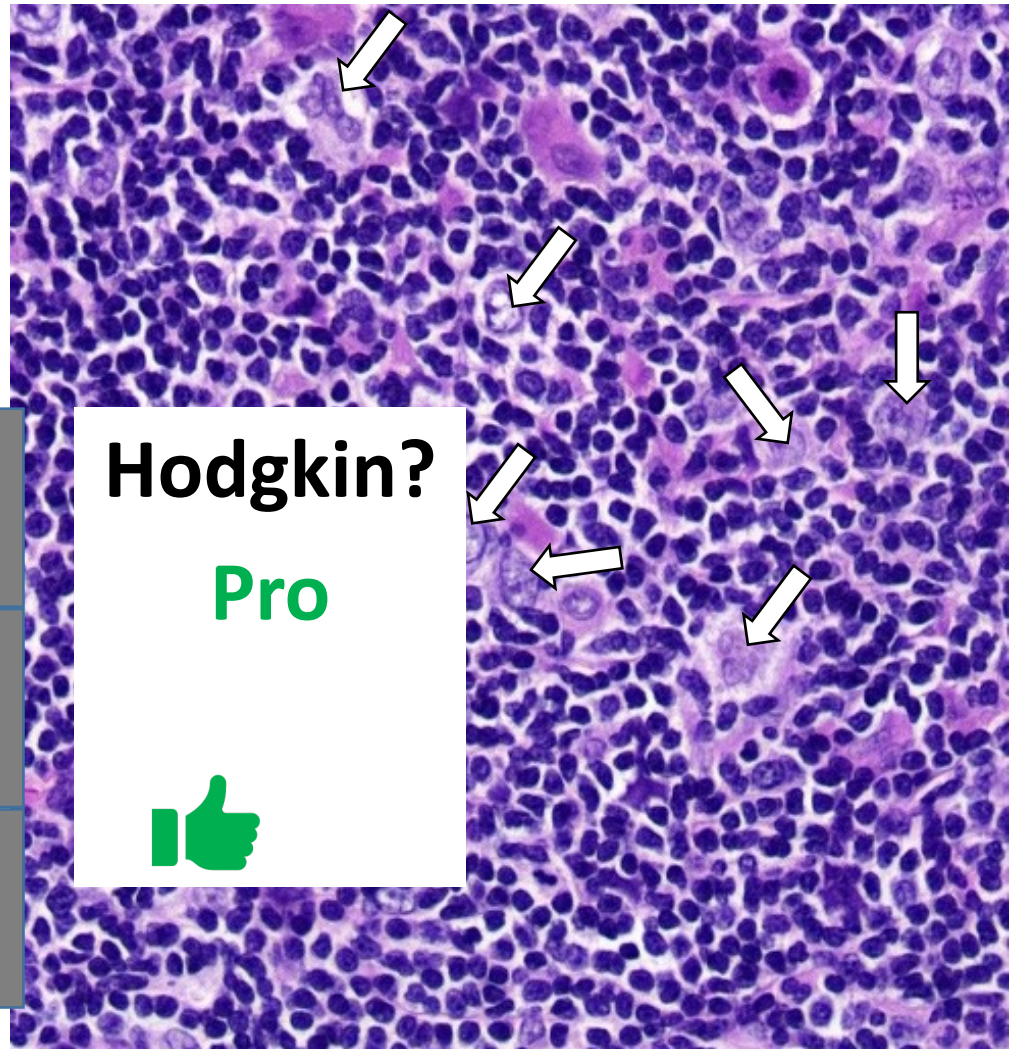

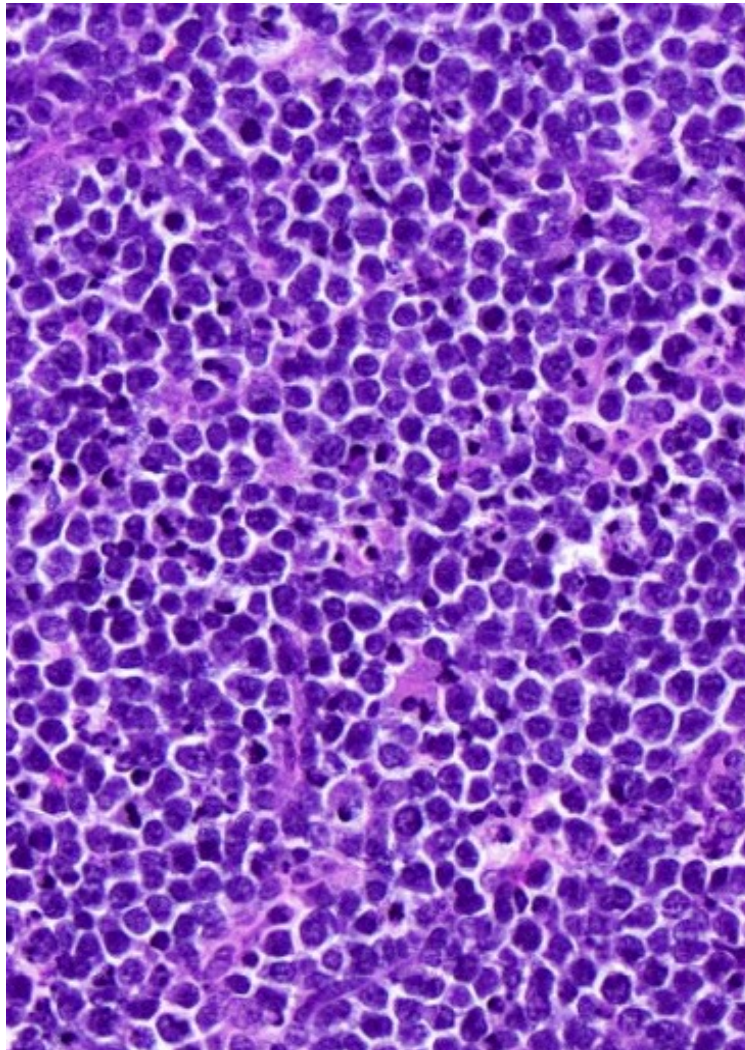

Immunophenotype

cHL	NLPHL/NLPBL	DLBCL

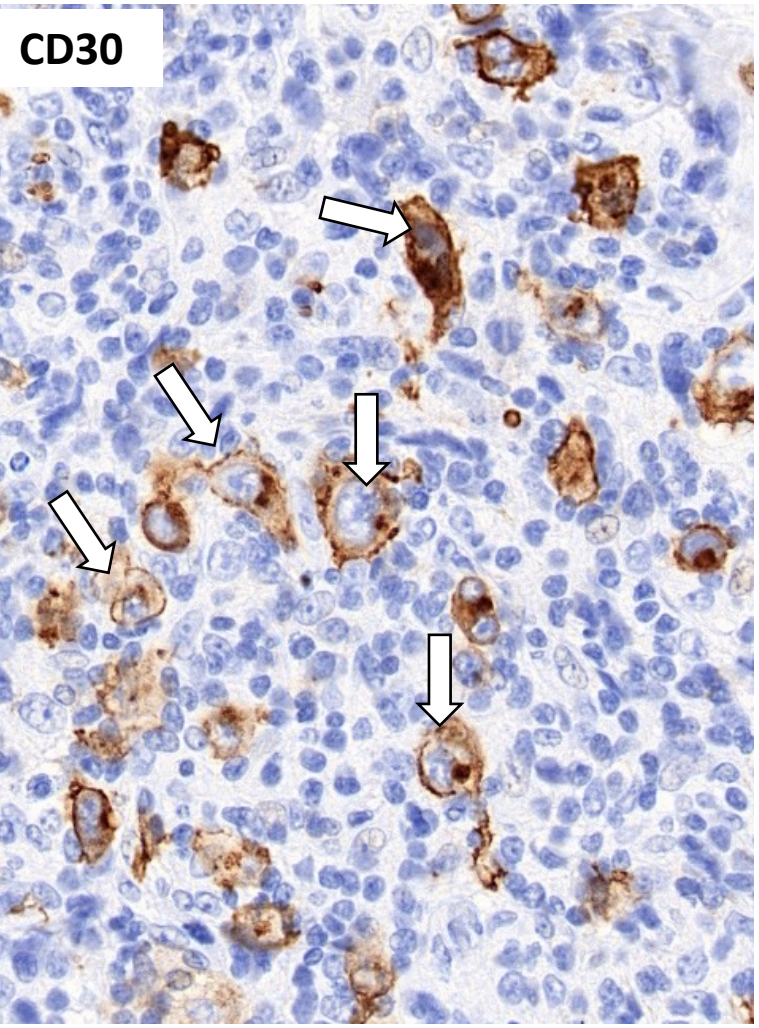

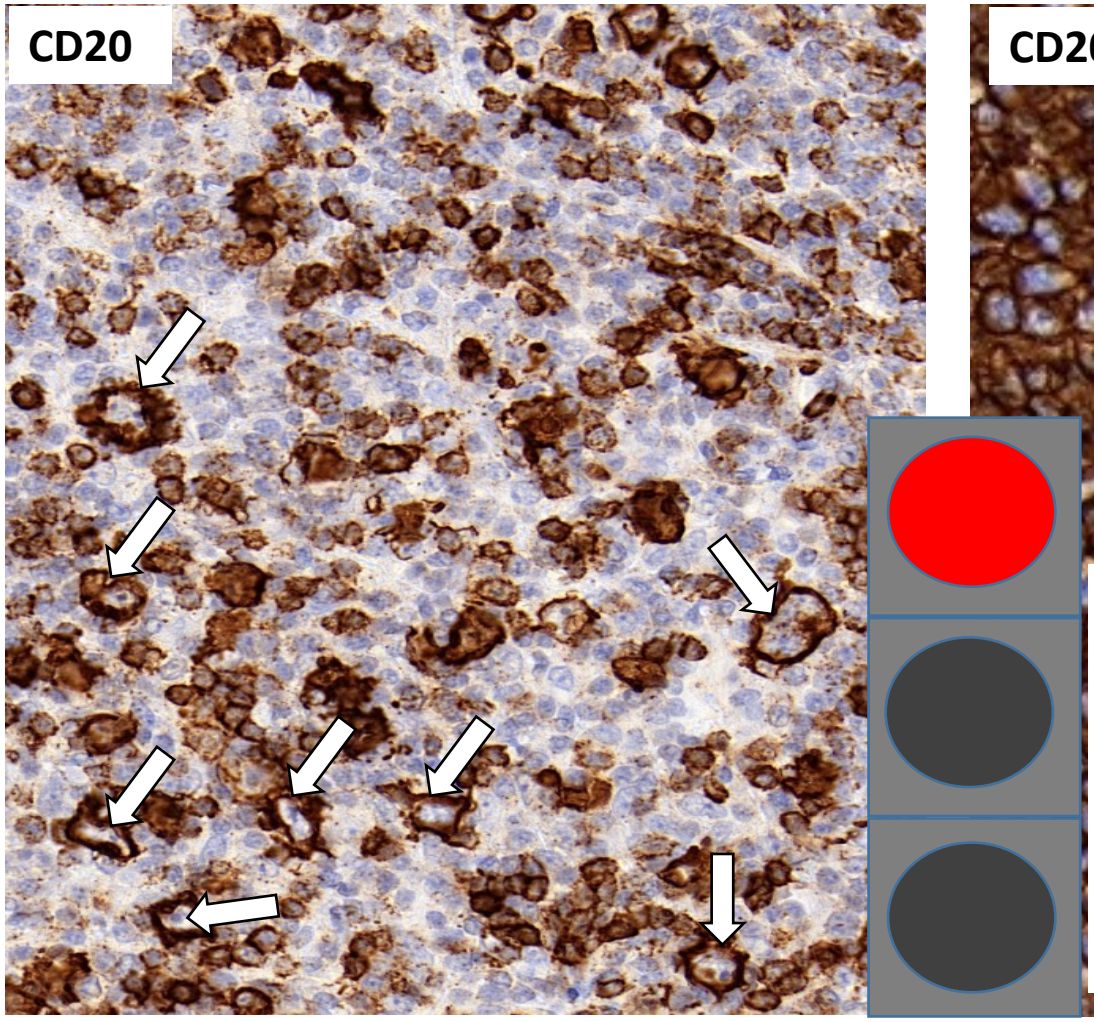

Partial loss of B cell identity in LP cells

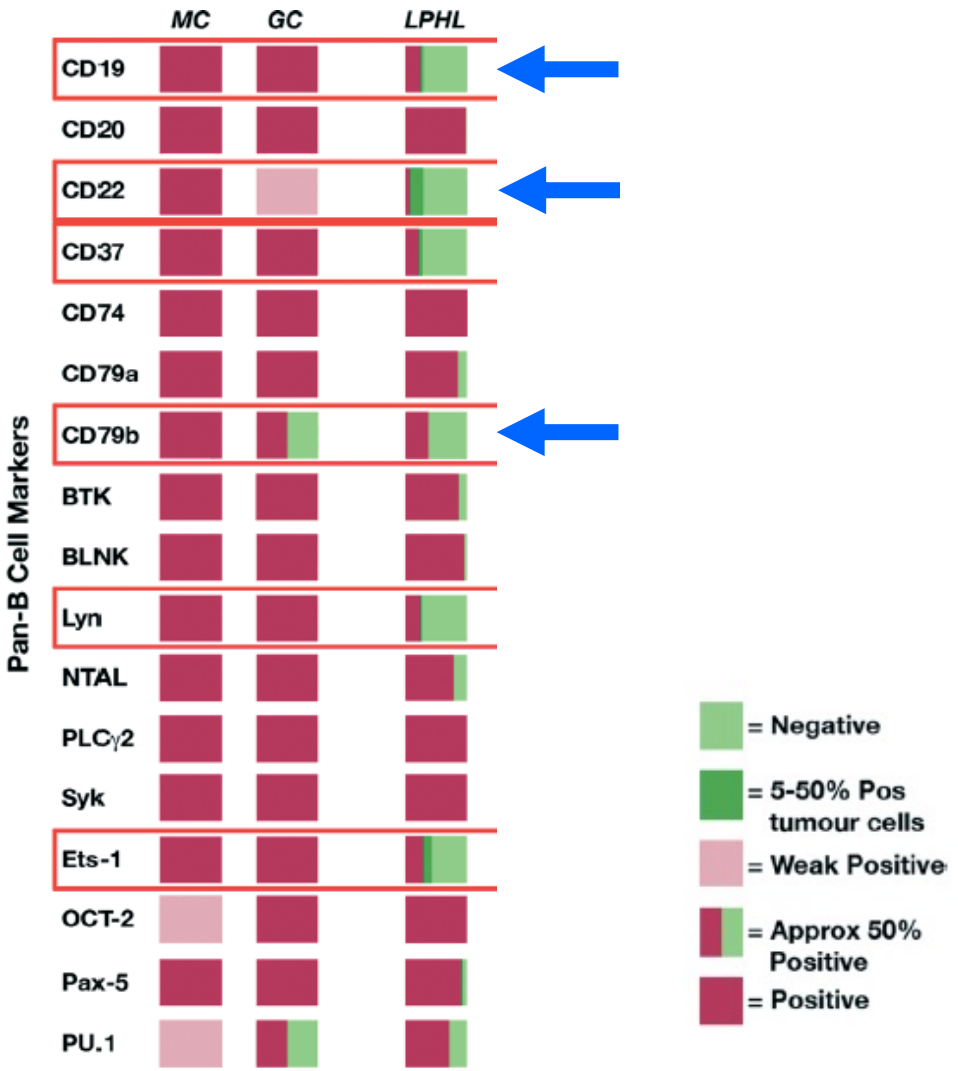



Hodgkin?

Pro

GEP
Brune et al., J Exp Med 2008

S Tedoldi,[1†] A Mottok,[2†] J Ying,[3] JC Paterson,[1] Y Cui,[3] F Facchetti,[4] JHJM van Krieken,[5] M Ponzoni,[6] S Özkal,[1] N Masir,[1] Y Natkunam,[7] SA Pileri,[8] M-L Hansmann,[2] DY Mason,[1‡] Q Tao[3‡] and T Marafioti[1*‡]

J Pathol 2007; **213**: 429–440

Principal component analysis from gene expression profiling of microdissected tumor cells

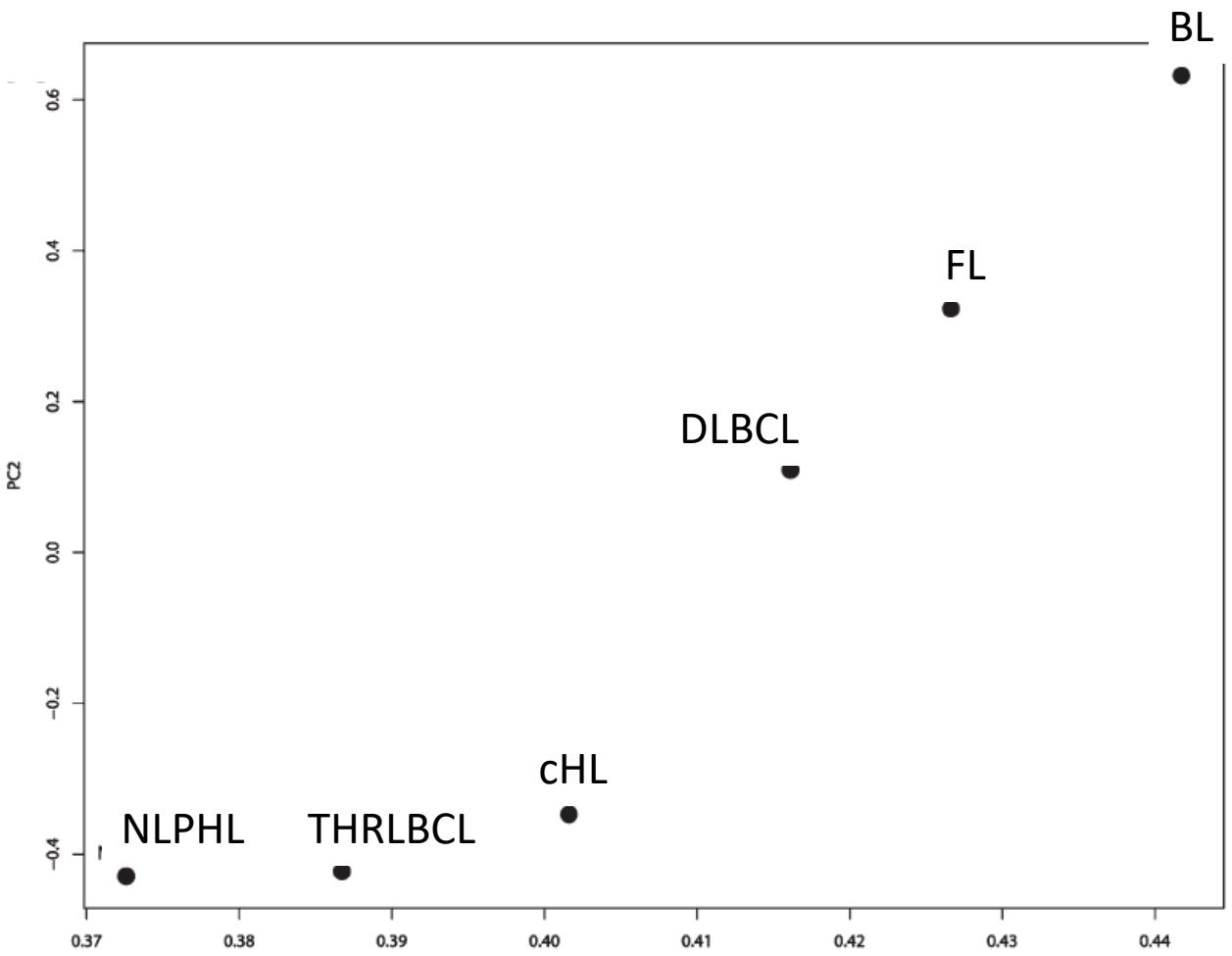



Hodgkin?

Pro

Principal component analysis from GEP Brune et al., J Exp Med 2008

NF-κB activity and JAK-STAT-signalling

cHL

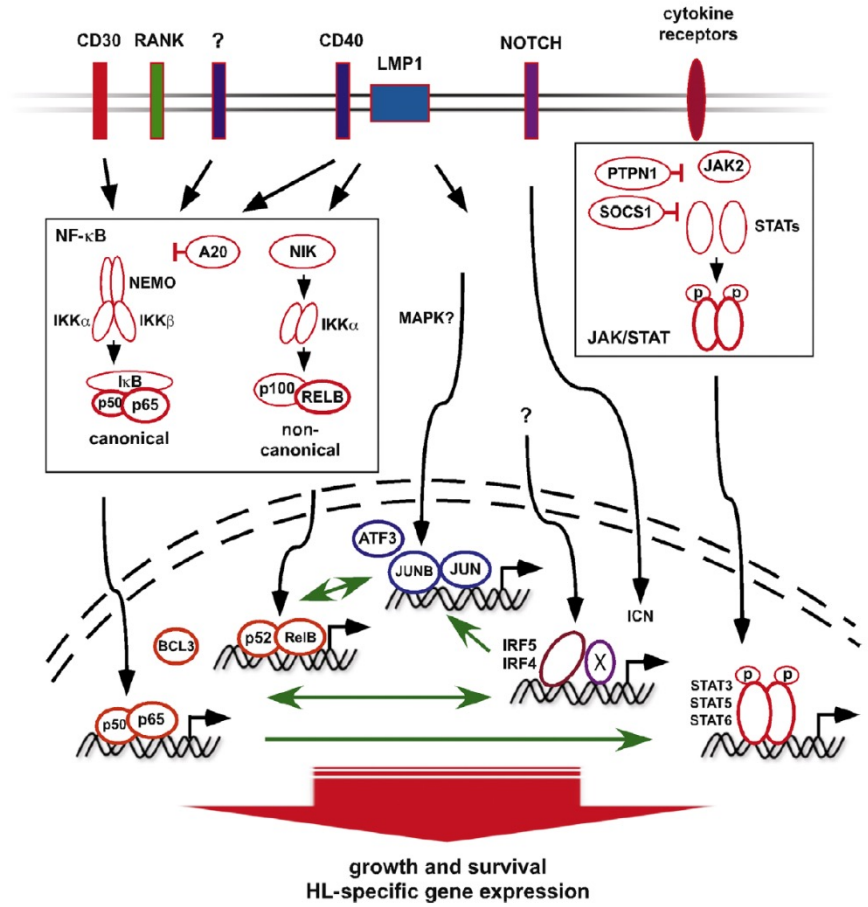

Mathas et al., Semin Hematol 2016

NLPHL/NLPBL

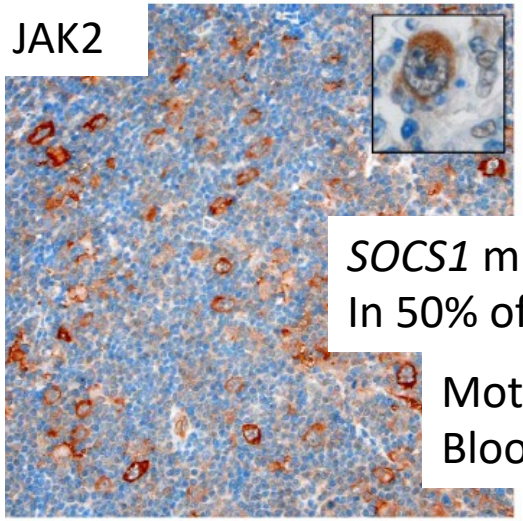

SOCS1 mutations
In 50% of cases

Mottok et al., Blood 2007

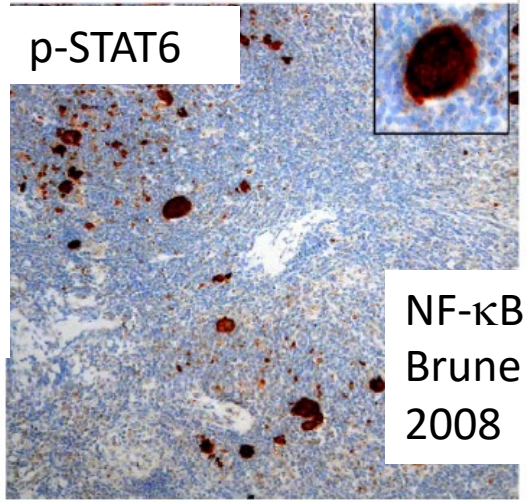

NF-κB activity
Brune et al., J Exp Med 2008

DLBCL

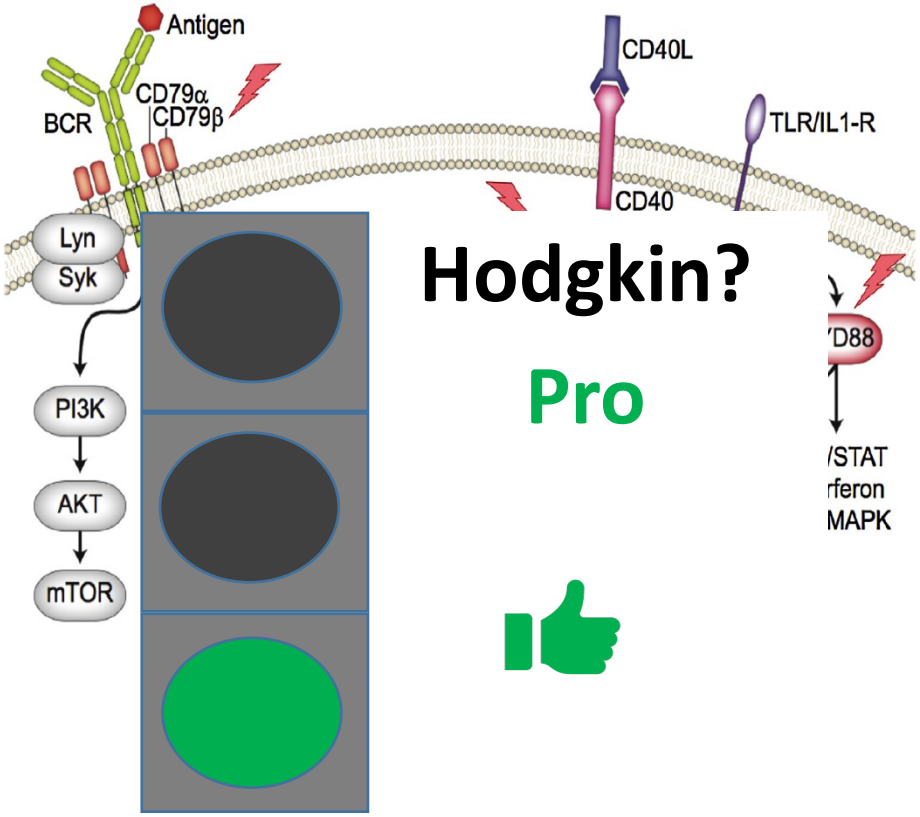

Pasqualucci et al., Semin Cancer Biol 2016

B-cell receptors of LP cells from NLPHL recognize bacterial antigens from *M. catarrhalis* or *R. mucilaginosa*

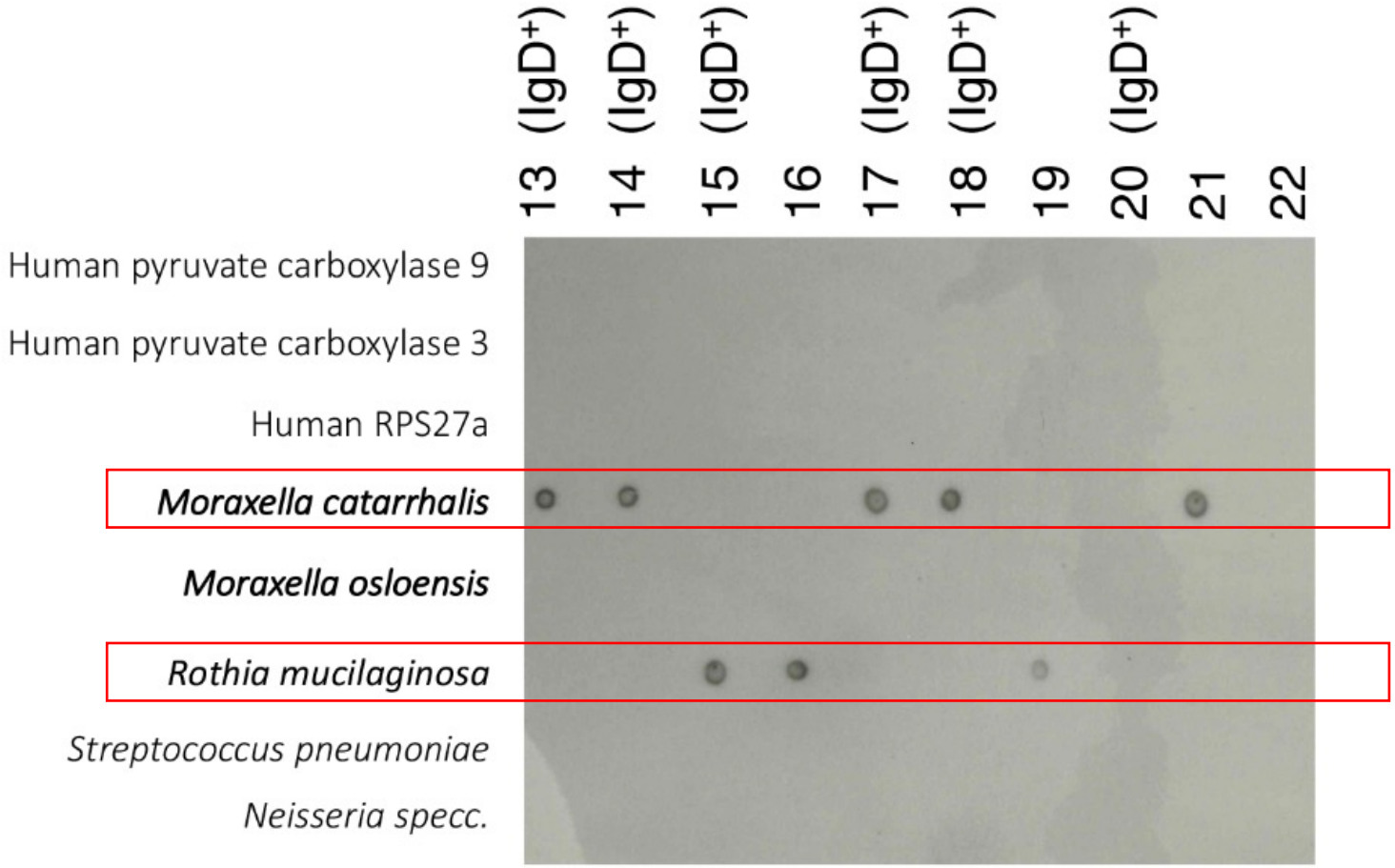

Prof. Lorenz Thurner, Homburg/Saar

Thurner*, Hartmann* et al., Nat Commun 2020

Thurner, et al. Hartmann, Haematologica 2023

Role of microenvironment

Hodgkin in live cell imaging

Classic HL

PD1 cells
HRS cells

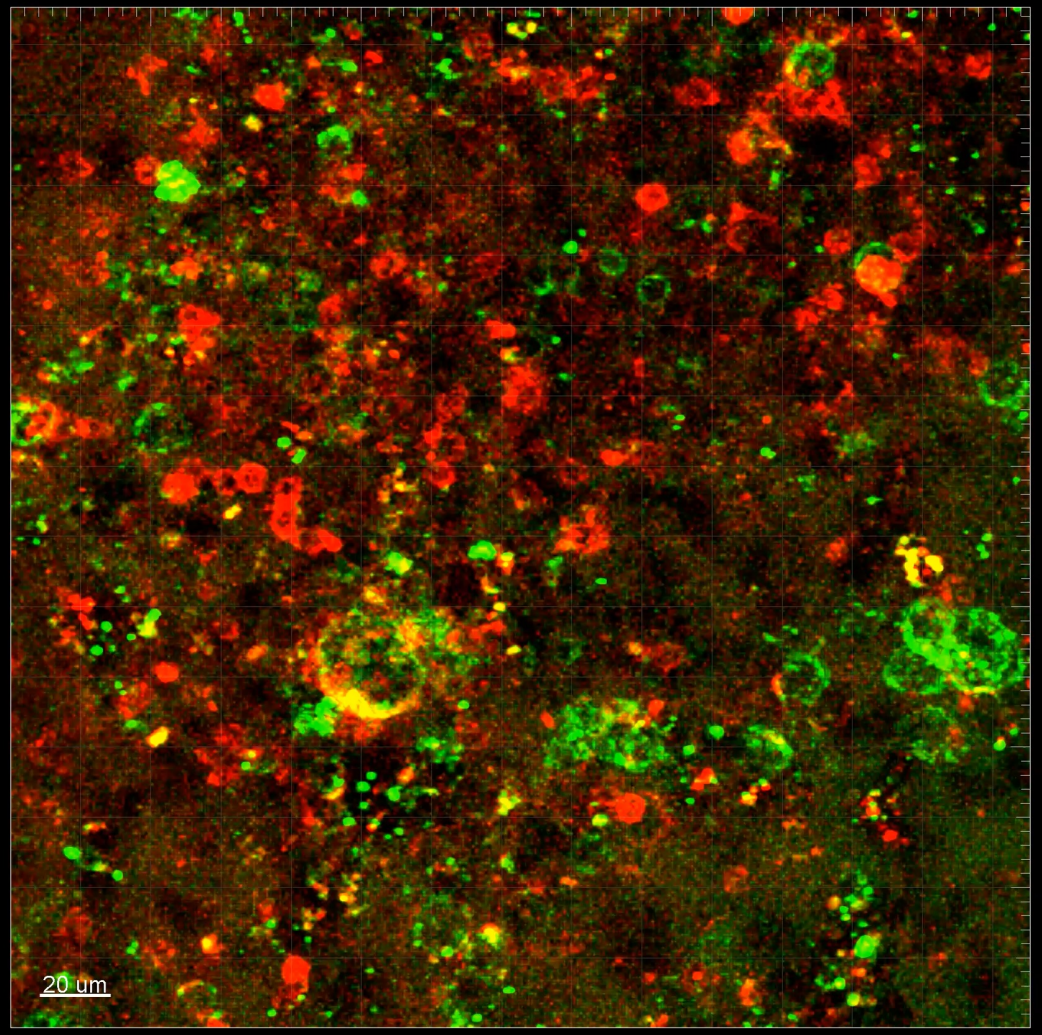

NLPHL/NLPBL

PD1 cells
LP cells

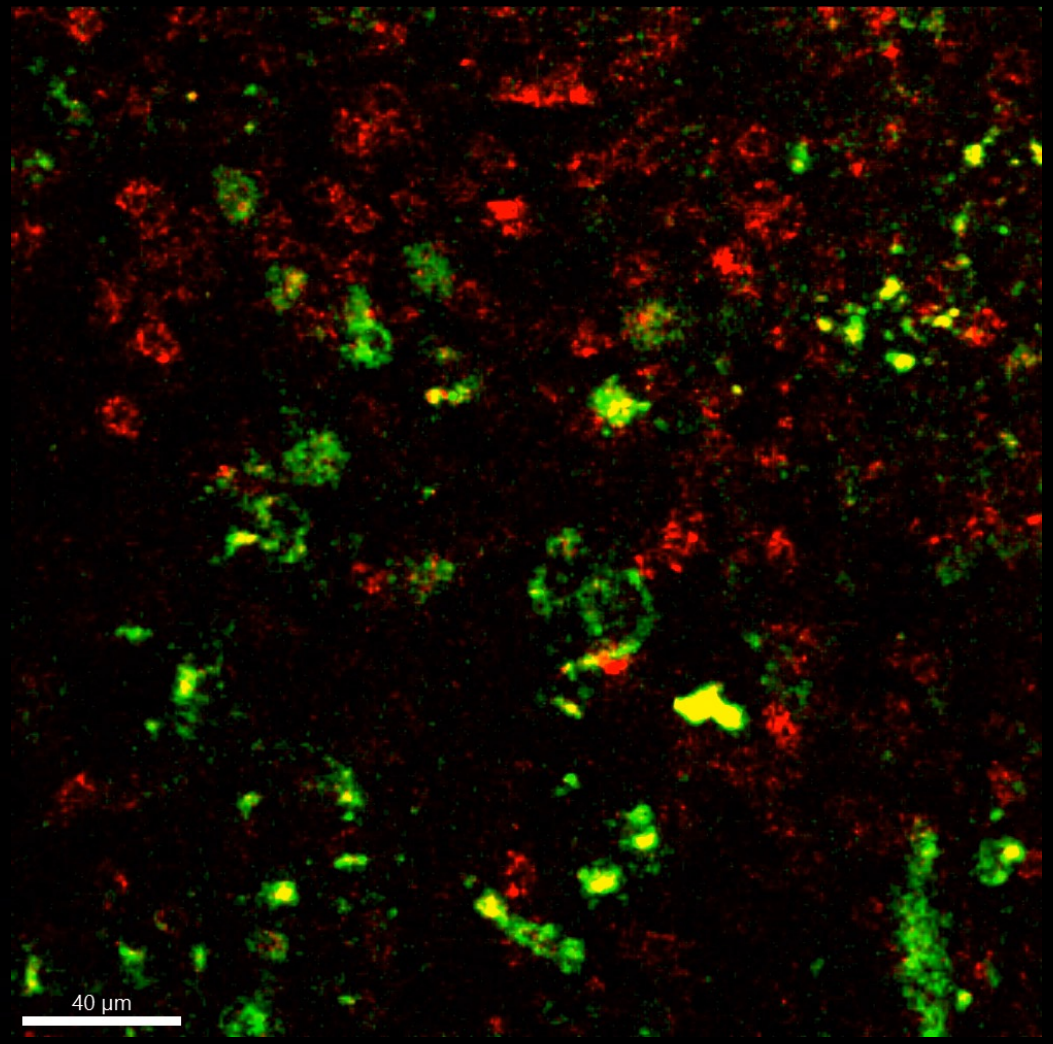

Hartmann et al. Cancers 2021

T-cell tracks live cell imaging

Classic HL

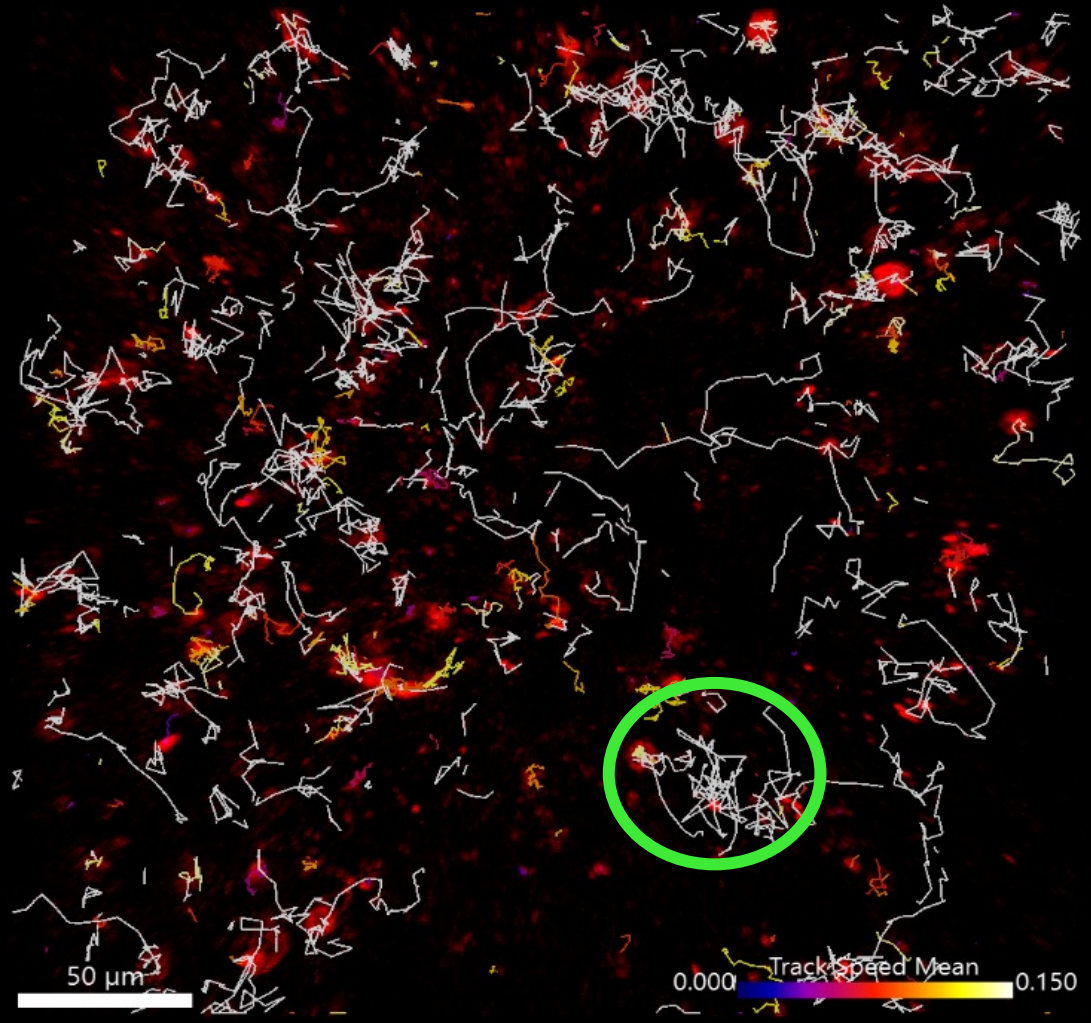

NLPHL/NLPBL

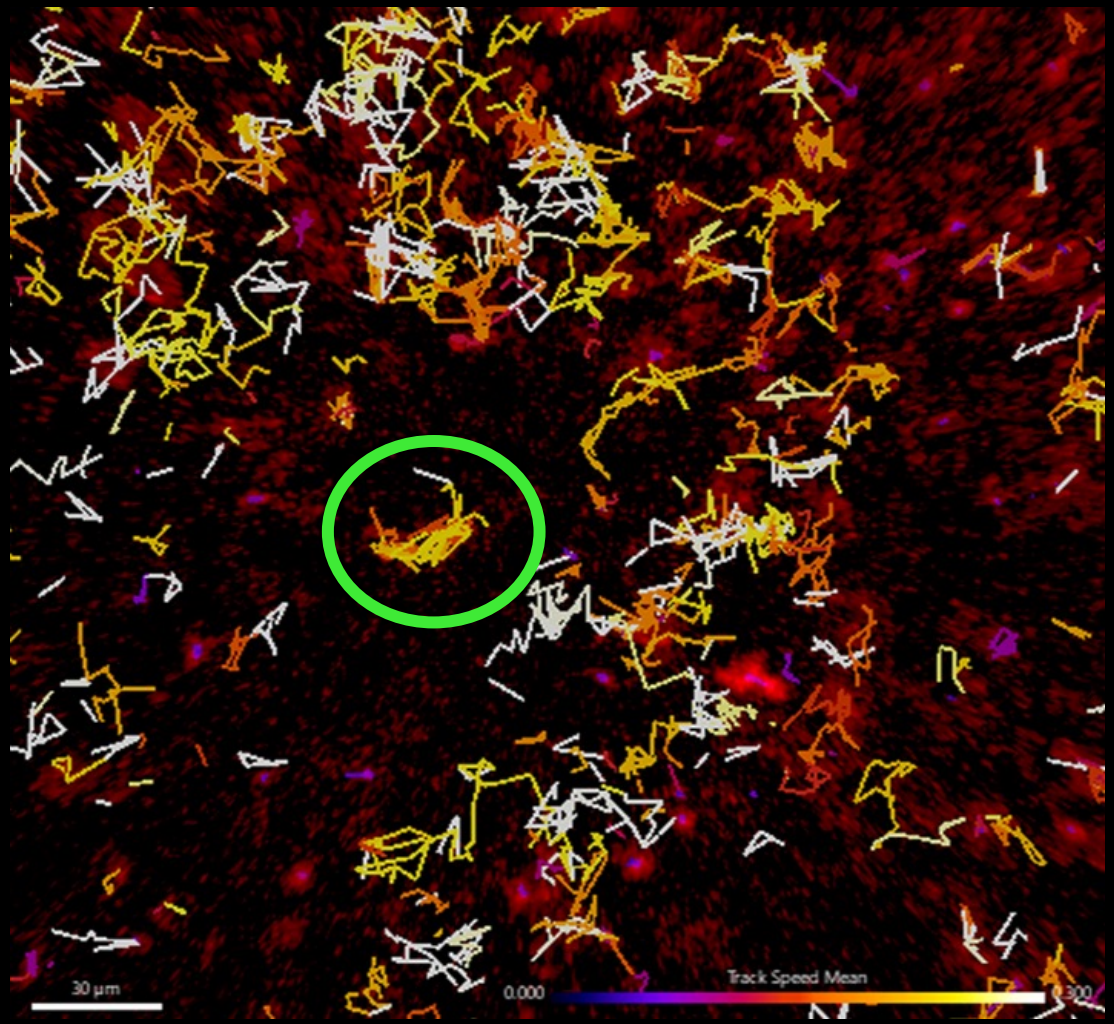

Hartmann et al. Cancers 2021

Immunological synapse formation in T-cell rosettes

Classic HL

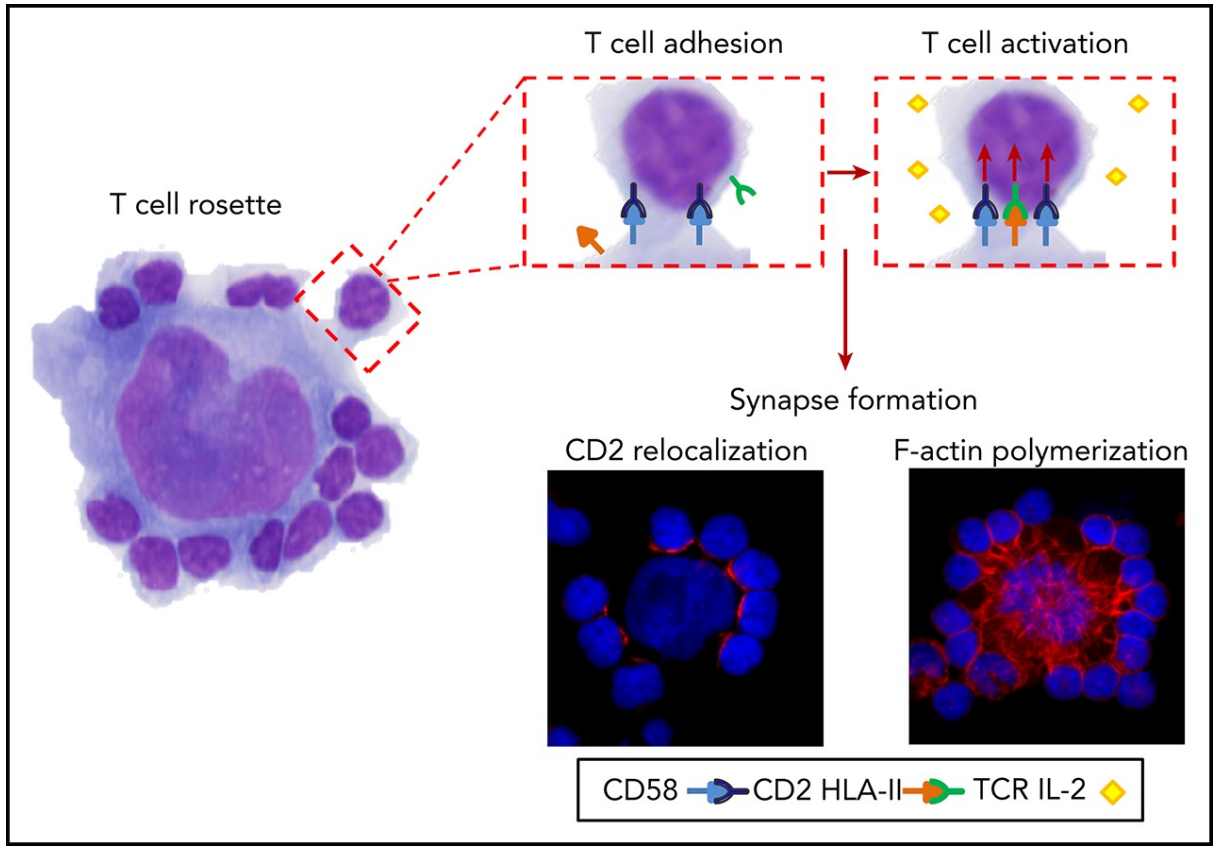

Johanna Veldman, Lydia Visser, Magdalena Huberts-Kregel, Natasja Muller, Bouke Hepkema, Anke van den Berg, Arjan Diepstra

Blood, 2020

NLPHL/NLPBL

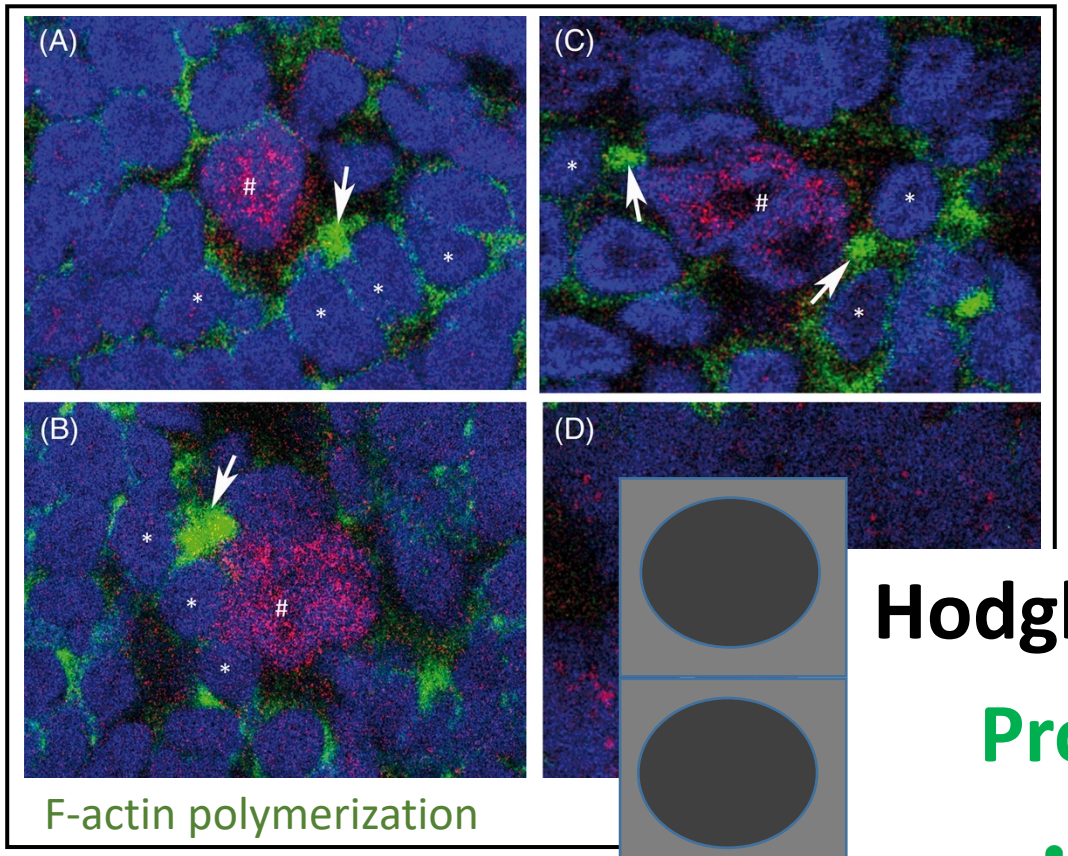

Julia Bein, Lorenz Thurner Hansmann, Sylvia Hartmar

Am J Hematol, 2020



Hodgkin?

Pro

Conclusions

- Classic Hodgkin lymphoma is clearly defined, numerous mimickers have to be recognized
- NLPHL/NLPBL is a unique lymphoma: it has both Hodgkin- and B-cell features
- NLPHL/NLPBL is a usually curable disease of often young patients
- Based on movement patterns and molecular data NLPHL/NLPBL is closer to cHL than to other B-cell lymphomas
- Personal opinion: Recognition effect within the Hodgkin's group higher than between ~ 40 mature B-cell lymphomas

DFG
Deutsche Forschungsgemeinschaft

Frankfurt
Peter Wild
Martin-Leo Hansmann
Julia Bein
Vivienne van Oostendorp
Yvonne Steiner
Aresu Sadeghi
Sajad Soltani
Sonja Scharf
Hendrik Schäfer
Thomas Oellerich
Uta Brunnberg
Teresa Halbsguth

GHSG - Cologne
Dennis Eichenauer
Annette Plütschow
Andreas Engert

Homburg/Saar (MED I)
Lorenz Thurner
Moritz Bewarder
Michael Pfreundschuh
Viola Pöschel
Rainer Maria Bohle

Reference pathologists
Martin-Leo Hansmann
Wolfram Klapper
Harald Stein
Andreas Rosenwald
Peter Möller
Alfred Feller
German Ott
Falko Fend
Sergio Cogliatti
Stefan Dirnhofer

Heidelberg (EMBL)
Vladimir Benes
Tobias Rausch

Essen
Ralf Küppers

Paris
Matthieu Piel
Emmanuel Donnadieu

Uppsala
Christer Sundström

Leuven
Thomas Tousseyn

Milan
Stefano Pileri

Tampere
Martine Vornanen

Brescia
Fabio Facchetti
Luisa Lorenzi

Lausanne
Laurence de Leval

Differential Diagnosis

NLPHL by WHO-HAEM-5

Essential

- Nodular architecture, at least focally
- LP tumour cells
- several B-cell antigens positive (usually CD20-positive).
- Immune microenvironment

Desirable

- PD1+ rosetting T cells
- Defining growth patterns (A-F).

THRLBCL by WHO-HAEM-5

Essential

- Diffuse effacement of lymph node architecture
- Singly scattered large B cells, without formation of aggregates
- Reactive background rich in histiocytes and small T cells, with no (or few) scattered small B cells.
- Absence of FDC meshworks by CD21 or CD23 stain.
- Absence of nodular lymphocyte predominant Hodgkin lymphoma.

Desirable

- Lymph node excision is preferred
- Exclude EBV association